


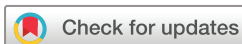BMJ Open Intraoperative visualisation and treatment of salivary glands in Sjögren's syndrome by contrast-enhanced ultrasound sialendoscopy (CEUSS): protocol for a phase I single-centre, single-arm, exploratory study

K Hakki Karagozoglu ¹, Marco Helder,¹ Joseph Bot,² Otto Kamp,³ Tim Forouzanfar,¹ Henk S Brand,⁴ Seunghee Cha,⁵ Gary Weisman,⁶ Imke Bartelink,⁷ Arjan Vissink,⁸ Derk Hendrik Jan Jager ¹

To cite: Karagozoglu KH, Helder M, Bot J, *et al*. Intraoperative visualisation and treatment of salivary glands in Sjögren's syndrome by contrast-enhanced ultrasound sialendoscopy (CEUSS): protocol for a phase I single-centre, single-arm, exploratory study. *BMJ Open* 2020;**10**:e033542. doi:10.1136/bmjopen-2019-033542

► Prepublication history for this paper is available online. To view these files, please visit the journal online (<http://dx.doi.org/10.1136/bmjopen-2019-033542>).

Received 13 August 2019
Revised 01 August 2020
Accepted 13 August 2020



© Author(s) (or their employer(s)) 2020. Re-use permitted under CC BY-NC. No commercial re-use. See rights and permissions. Published by BMJ.

For numbered affiliations see end of article.

Correspondence to
K Hakki Karagozoglu;
kh.karagozoglu@amsterdamumc.nl

ABSTRACT

Introduction We established a promising sialendoscopic treatment for in vivo enhancement of salivation in salivary glands affected by Sjögren's syndrome (SS). In this technique, the ducts of the salivary glands are irrigated with saline and steroids. This allows for dilatation of ductal strictures and removal of debris. Unfortunately, it is not possible to assess the delivery and penetration of saline or medications in the ductal system and parenchyma. To address this problem, we will conduct contrast-enhanced ultrasound sialendoscopy (CEUSS) using sulphur hexafluoride microbubbles. To the best of our knowledge, microbubbles have never been used for the treatment of salivary glands in SS. It is, therefore, imperative to test this application for its safety and feasibility.

Methods and analysis A single-arm phase I study will be performed in 10 SS patients. Under local anaesthesia, ultrasound (US) guided infusion of the parotid and submandibular glands with microbubbles will be performed. Continuous US imaging will be used to visualise the glands, including the location of strictures and occlusions. Main outcomes will be the evaluation of safety and technical feasibility of the experimental treatment. Secondary outcomes will consist of determinations of unstimulated whole mouth saliva flow, stimulated whole mouth saliva flow, stimulated parotid saliva flow, clinical oral dryness, reported pain, xerostomia, disease activity, salivary cytokine profiles and clinical SS symptoms. Finally, salivary gland topographical alterations will be evaluated by US.

Ethics and dissemination Ethical approval for this study was obtained from the Medical Ethics Committee of the Amsterdam University Medical Centre, Amsterdam, The Netherlands (NL68283.029.19). data will be presented at national and international conferences and published in a peer-reviewed journal. The study will be implemented and reported in line with the Standard Protocol Items: Recommendations for Interventional Trials' statement.

Strengths and limitations of this study

- This will be the first study to examine the safety and technical feasibility of microbubbles, combined with sialendoscopy, in salivary glands of patients with Sjögren's syndrome.
- This is a 'single-arm' trial. The data will be used to inform a future's large multi-centre randomised controlled trial comparing different treatment options.
- The present study is a non-randomised phase I trial; therefore, the results cannot be confirmatory, but will be indicative of the benefits of contrast-enhanced ultrasound sialendoscopy.
- The present study does not compare other techniques or protocols.

Trial registration numbers The Netherlands Trial Register: NL7731, MREC Trial Register: NL68283.029.19; Pre-results.

INTRODUCTION

Sjögren's syndrome (SS) is an autoimmune disorder causing chronic inflammation and irreversible damage of the exocrine glands. SS is characterised by mononuclear infiltrates and immunoglobulin G plasma cells in salivary and lacrimal glands, which leads to irreversible destruction of glandular tissue.¹ SS affects 0.3–1 of 1000 persons with a female to male ratio of 9:1.^{2,3} SS causes a gradual reduction in the quantity and quality of saliva.⁴ Because of hyposalivation, patients with SS suffer from a sensation of oral dryness (xerostomia) and its related complaints (difficulty in eating and swallowing, altered taste and speech problems). They are also prone to developing progressive dental decay and



chronic inflammation of the oral mucosa.⁵ Additionally, patients suffer from painful episodes of sialadenitis due to partial or complete obstruction of the saliva-transporting ducts caused by intraductal scar formation and fibrinous plaques.^{6–8}

In recent years, we have established a promising sialendoscopic treatment of salivary-gland-related complications in patients with SS. In this technique, the ducts of the salivary glands are irrigated with saline and steroids. This minimally invasive technique allows dilatation of ductal strictures and removal of ductal debris. We showed alleviation of some of the oral symptoms of patients suffering from SS and partial restoration of glandular function (ie, saliva flow).^{9–11}

Although sialendoscopy in patients with SS has shown promising results, there are several limitations in the current approach. It is not possible to enter and explore all ducts with the current sialendoscopes because of decreasing ductal diameters from the main duct to terminal glandular tissue. In addition, it is difficult to intraoperatively evaluate therapeutic efficacy (ie, removal of obstructions and restoration of flow) and to assess the delivery and deep penetration of medication in the ductal system and parenchyma.

To address these limitations of sialendoscopy and to improve our therapy, we will conduct contrast-enhanced ultrasound sialendoscopy (CEUSS) using commercially available sulphur hexafluoride microbubbles (SonoVue Bracco Imaging SpA, Milan, Italy). These microbubbles, consisting of 5–10 µm gas-filled particles, were initially used as contrast agents to demonstrate occlusions of fluid flow, but are currently also being used in the cardiology field to dissolve arterial occlusions.^{12–15} The proposed mechanism of action is that microbubbles can oscillate under the influence of ultrasound (US).

In our approach, the microbubbles will serve multiple purposes. (1) The micrometre size of the microbubbles facilitates penetration into virtually all ducts, thereby allowing non-invasive high-resolution US imaging of the glands and, in particular, ductal obstructions (where microbubbles will accumulate). (2) The effect of US-enhanced sialendoscopy can be imaged directly by re-infusion of microbubbles to assess the 'new' distribution pattern. If ductal obstructions have not yet been sufficiently resolved, treatment can be repeated in the same session. (3) The level of glandular inflammation may concomitantly be reduced.

The sialendoscopic treatment we use currently resolves some SS symptoms, and we have evidence that sialendoscopy significantly improve low saliva flow in patients with SS, thereby reducing their oral dryness burden.^{10 11} Sialendoscopy is a minimally invasive technique, which is clinically accepted to treat obstructive salivary gland diseases. The current project has the added value over normal sialendoscopy in that it encompasses non-invasive intraoperative visualisation and diagnostic imaging without exposure of patients to radiation, and

we hypothesise that the irrigation-induced local hydrostatic pressure dissolves ductal occlusions and enhances saliva flow.

Microbubbles are widely used for various applications, both as a contrast agent and as a treatment modality. They have been used for US-assisted contrast imaging in salivary glands^{16 17} but are not for US-assisted contrast imaging in salivary glands affected by SS. It is, therefore, imperative that this new application is first tested for its feasibility and safety in a cohort of patients with SS.

The aim of this study is to assess the safety and practical applicability of CEUSS in the salivary glands of patients with SS. Practical applicability will be defined as accomplishment of the experimental protocol during the procedure. To evaluate functional outcomes, we will meticulously monitor for serious adverse events (SAEs) and assess whether changes in saliva flow, oral dryness indices and subjective mouthfeel occur. This evaluation will be performed in a phase I, single-centre, single-arm, exploratory study. The study protocol will be implemented and reported in line with the Standard Protocol Items: Recommendations for Interventional Trials' statement.¹⁸

METHODS AND ANALYSIS

Study setting

This single-centre trial will be performed at the Departments of Oral and Maxillofacial Surgery/Oral Pathology and Radiology and Nuclear Medicine, Amsterdam University Medical Centre, VU University Amsterdam, Amsterdam, the Netherlands.

Participants and eligibility criteria

Participants will be recruited from our existing database of patients with SS. To be eligible to participate in this study, a subject must meet all of the following criteria: diagnosed with primary SS in agreement with the 2016 American College of Rheumatology–European League Against Rheumatism (EULAR)¹⁹; age: ≥18 years and ≤75 years; a remaining unstimulated whole mouth saliva flow (UWSF) of ≥0.02 mL/min and a remaining stimulated whole mouth saliva flow (SWSF) of ≥0.10 mL/min.

Potential subjects who meet any of the following criteria will be excluded from participation in this study: we are unable to identify or enter the orifice of the salivary duct(s), as determined during assessment, 6 weeks before intervention (table 1); acute sialadenitis; severe illness or physical conditions interfering with the intervention; use of sialogogue medication (ie, pilocarpine or cevimeline); a history of head and neck cancer radiotherapy; presence of MALT lymphoma in the major salivary glands; suspected acute coronary syndrome; recent percutaneous coronary intervention; acute or chronic severe (New York Heart Association (NYHA) class III/IV) heart failure; right-to-left shunts; severe pulmonary hypertension (pulmonary artery pressure >90 mm Hg); uncontrolled hypertension; adult respiratory distress syndrome or severe cardiac dysrhythmias. The microbubbles used in

Table 1 Schedule of enrolment, interventions and assessments

Timepoint (weeks)	Baseline assessment		Post-intervention assessment				
	Enrolment T-6	T-4	T0	T1	T2	T8	T16 (closeout)
Enrolment							
Eligibility screen	X						
Informed consent		X					
Interventions							
CEUSS			X				
Assessments							
Safety				X	X	X	X
Technical feasibility and applicability			X				
UWSF, SWSF and SPSF	X	X		X	X	X	X
Analysis of the salivary cytokine profiles		X		X	X	X	X
CODS		X		X	X	X	X
XI score		X		X	X	X	X
ESSPRI score		X		X	X	X	X
MPQ		X		X	X	X	X
Salivary gland topography		X		X			X

CEUSS, contrast-enhanced ultrasound sialendoscopy; CODS, Clinical Oral Dryness Score; ESSPRI, European League Against Rheumatism (EULAR) Sjögren's Syndrome Patient Reported Index; MPQ, McGill Pain Questionnaire; SPSF, stimulated parotid saliva flow; SWSF, stimulated whole mouth saliva flow; T-6, 6 weeks before intervention; UWSF, unstimulated whole mouth saliva flow; XI, Xerostomia Inventory.

this study should not be used in combination with dobutamine in patients with cardiovascular instability, where dobutamine is contraindicated.

Patients are asked to participate in the study by a maxillofacial surgeon or dentist (ie, investigators) at their first consultation appointment. At this time, the investigators will explain the study and provide the volunteers with the participant information and the informed consent letter. At the next appointment, there is the opportunity to ask questions about the study and volunteers can indicate whether they want to participate. If the participant wants to participate, they will sign the informed consent form (online supplemental file 1). The investigators also will sign the informed consent form. The anticipated date of first enrolment is July 2020.

Intervention

CEUSS is a classic endoscopic technique combined with US imaging, specially designed for application in large salivary glands. In every patient, under local anaesthesia, a US-guided infusion of microbubbles (SonoVue, Bracco Imaging SpA, Milan, Italy) into the parotid and submandibular glands will be performed followed by activation of the microbubbles by US. A mixture of 0.3 mL of a second-generation contrast agent (SonoVue, Bracco, Milan, Italy) consisting of stabilised microbubbles of sulphur hexafluoride and 9.5 mL (0.9% w/v NaCl) will be used as the irrigation solution. After the orifice of the salivary gland duct to be treated is located, 0.5–1.0 mL of 4% (w/v) articaine with 1:100 000 epinephrine

(Septanest, Septodont, Saint-Marud-Fosses, France) is injected submucosally near the papilla. Next, the endoscope is properly positioned in the salivary duct under echoscopic guidance. Sialendoscopy with continuous US imaging will be performed using 0.8 mm or 1.1 mm diameter Erlangen sialendoscopes (Karl Storz GmbH & Co, Tuttlingen, Germany). Sialendoscopy is always started by flushing the salivary duct system and filling it with approximately 2 mL of irrigation solution to unfold the ducts. During sialendoscopy, irrigation fluid will continuously drain in a retrograde manner from the duct system via the ostium into the oral cavity and it is removed from the oral cavity by suction. Therefore, the irrigation fluid has to be replenished regularly throughout the procedure. For this, a small volume of irrigation fluid will be applied whenever the ducts collapse. This strategy results in an average application rate of about 0.5 mL irrigation fluid per minute.²⁰ Stronger and longer lasting bursts of irrigation may be necessary during endoscopy to flush out plaques and microsialoliths from the salivary duct system and open strictures. On the surgeon's instruction, the assisting nurse will perform intermittent flushing by manual pressure on the 10 mL syringe. Finally, an intraductal bolus injection of the remaining irrigation solution will be administered under direct vision into the salivary glands and maintained in the glands by temporarily (± 10 min) occluding the ductal orifices with a microvascular clamp. During the procedure, continuous US imaging will be performed using a local transdermal US device to

visualise the glands, including the location of strictures and occlusions. This will be performed at a fixed US resonance frequency of 9 MHz, performed under low US mechanical index settings (eg, MI: 0.1), to avoid disruption and premature activation of the bubbles.¹⁷ It will be visualised how far and how quick the microbubbles enter the ductal system of the salivary glands and the effect of the sialendoscopic rinsing procedure on strictures (ie, occlusions or blockades) will be monitored.

Outcomes

Main outcomes will be an evaluation of the safety and practical applicability of the experimental treatment. Safety will be determined by unanticipated treatment-related mortality, and the occurrence of adverse events (AEs) and SAEs. AEs will be defined as any undesirable experience occurring to a subject during the experimental treatment period, whether or not related to the investigational intervention. SAEs will be defined as any untoward medical occurrence or effect that, at any dose, is life threatening (at the time of the event); requires hospitalisation or prolongation of existing in-patients' hospitalisation; results in persistent or significant disability or incapacity or is a new event of the trial likely to affect the safety of the subjects, such as an unexpected outcome of an adverse reaction. Practical applicability will be defined as accomplishment of the experimental protocol during the procedure.

Exploratory outcomes of CEUSS will include measurements of UWSF, SWSF, stimulated parotid saliva flow and the Clinical Oral Dryness Score (CODS).^{21 22} Changes due to CEUSS in reported pain, mouthfeel and clinical SS symptoms will be determined in comparison to initial values using a set of validated questionnaires, that is, the McGill Pain Questionnaire (MPQ),²³ Xerostomia Inventory (XI)²⁴ and EULAR Sjögren's Syndrome Patient Reported Index (ESSPRI).^{25 26} Furthermore, changes in salivary cytokine profiles will be determined (interleukin (IL) 1 β , IL-6, B-cell Activating Factor (BAFF), IL-12, IL-18 and Tumor Necrosis Factor α (TNF α)). Finally, salivary gland topographical alterations will be evaluated by US using the Hočevar Score.²⁷ The echostructure of the treated glands will be graded at T-4 (4 weeks before intervention), T1 (1 week after intervention) and T16 (16 weeks after intervention).

Participant timeline

The study encompasses an enrolment and assessment period of 6 weeks and a patient follow-up period of 16 weeks. The schedule of enrolment, interventions and assessments is presented in [table 1](#).

Sample size

Ten patients will be included. Usually, 10–20 patients are usually investigated in a phase I trial to confirm the occurrence of toxic effects or (S)AEs that are anticipated to be <20%.

Data collection methods

Saliva flow and analysis

Each patient will be instructed to refrain from drinking, eating, chewing, brushing teeth and smoking for 90 min before each visit. To minimise diurnal variation, all appointments for each patient will be at the same time of day and in the same room (temperature: 21°C \pm 2°C and humidity: 50%–60%). UWSF and SWSF samples will be collected every 30 s over 5-minute periods in separate pre-weighed containers placed in crushed ice to prevent proteolysis. For the UWSF samples, each patient will be instructed to start collecting saliva immediately after an initial swallow and expectoration. For the SWSF samples, patients will be instructed to chew a 5 \times 5 cm sheet of paraffin (ParafilmM, Pechiney, Chicago, Illinois, USA) and then expectorate. The patients are instructed to chew at a rate of 60 strokes/min, which is indicated by a metronome. This chewing rate reflects a normal chewing rate. Each container will be reweighed after saliva collection and the weight of the empty container will be subtracted to determine UWSF and SWSF rates (mL/min).²⁸ Parotid-stimulated saliva will be collected from each parotid gland using plastic tubes and modified Lashley cups. Citric acid (2% w/v) will be applied to the lateral border of the tongue using a cotton wool swab at 30-second intervals to stimulate parotid gland secretion.²⁹ The same observer will perform all assessments. See also the standard operating procedure in the supplemental materials (online supplemental file 2).

Saliva will be transferred to Eppendorf tubes (Eppendorf AG, Hamburg, Germany) and centrifuged for 5 min at 10 000 g at 4°C³⁰ to remove debris. After centrifuging, the saliva will be stored at –80°C in plastic containers (Cryogenic Vials Nalgene tubes, Nalgene Nunc, Rochester, New York, USA). Every volunteer will be given a labelled code of 1–10, based on the order of application. Only principal investigators can access the coded data. All samples will be stored for analysis of salivary cytokine profiles (IL-1 β , IL-6, BAFF, IL-12, IL-18 and TNF) by our collaborators (University of Florida and University of Missouri, USA).

XI score

The summated XI is an 11-item validated questionnaire about oral dryness and mouthfeel. A 5-point Likert scale is used to indicate symptom frequency. The values from the questions are summed to give a total XI score of 11 (no dry mouth) to 55 (extremely dry mouth).²⁴

European League Against Rheumatism (EULAR) Sjögren's Syndrome Patient Reported Index (ESSPRI)

Disease symptoms (pain, fatigue and dryness) will be assessed using the 10-point scale ESSPRI patient-administered questionnaire. The ESSPRI has high sensitivity for detection of changes in symptoms after a therapeutic intervention is performed. Only the dryness subscale will be included in the analysis. A change of 2 or more points is considered clinically relevant.^{25 26}

Clinical Oral Dryness Score (CODS)

The CODS is a validated clinical guide designed to assess oral dryness using clinical and visual inspection of the oral cavity. It includes clinical signs of oral dryness, such as the presence of frothy saliva and stickiness of the dental mirror to the tongue and buccal fold. The values for each of 10 characteristics will be summed to result in a score ranging from 0 (no oral dryness) to 10 (extreme oral dryness).^{21 22}

Pain score

The Dutch version of the MPQ is a three-part pain assessment tool that measures several dimensions of the patient's pain experience. The first part consists of an anatomic drawing of the human form on which the patient marks where his or her pain is located. The second part of the MPQ is a verbal descriptive scale that allows the patient to record the intensity level of his or her current pain experience. The third part of the MPQ is a pain verbal descriptor inventory consisting of 72 descriptive adjectives. The patient is asked to review this list of pain descriptors and circle the ones that serve to best describe his or her current pain experience. Each part or dimension of the MPQ is individually scored and a cumulative total score is also recorded.²³

Evaluation of the major salivary glands by US

The Hočevár scoring system will be used to investigate: (1) parenchymal echogenicity compared with the thyroid gland, graded 0–1; (2) homogeneity, graded 0–3; (3) the presence of hypoechoic areas, graded 0–3; (4) hyper-echogenic reflections, graded 0–3 in parotid glands and 0–1 in submandibular glands and (5) clearness of the salivary gland border, graded 0–3, in both parotid and submandibular salivary glands. Total US score is the sum of these five domains and can range from 0 to 48.²⁷

Data management and confidentiality

A data management plan, according to the findable, accessible, interoperable and reusable principles, will use Amsterdam University Medical Centre (UMC) Clinical Research Bureau (CRB) guidelines. We will make use of restricted access to the data. We will keep an electronic log of patients who fulfil the eligibility criteria, patients who are invited to participate in the study, patients recruited and patients who withdraw from the study. Reasons for non-recruitment will also be recorded. During the course of the study, we will document reasons for withdrawal and failure to follow-up. The data will be stored electronically in case report forms (CRFs) software with audit trail functionality and will be audited by the Institutional CRB. The Good Clinical Practice (GCP)/Good Manufacturing Practice (GMP) approved electronic CRF software will be from Castor EDC (Castor EDC, Amsterdam, the Netherlands).

Every volunteer will be marked with a number 1–10 (based on the order of application) for de-identification purposes. Only de-identified information will be stored

and participants will only be identifiable by their unique study numbers, which will be kept in a separate file. The data will be securely stored on these servers for 15 years according to national guidelines. The principal investigator will have access to the final trial data set.

Statistical methods

A descriptive analysis of the primary outcome measures (AEs and SAEs) will be performed. Wilcoxon signed-rank tests (data without a normal distribution) or linear mixed models (data with a normal distribution) will be used to examine differences between subsequent timepoints for the secondary outcome measures. Furthermore, estimates of the means and SD of the parameters listed in previous paragraphs will be used for determination of the sample size for a subsequent randomised controlled trial.

Data monitoring and auditing

An independent quality-monitoring official will monitor the data by the GCP guidelines. The informed consent forms of a selection of participants will be checked. During the onsite monitoring, Source Data Verification will be performed (a check if the data in the CRFs (research forms/questionnaires) matches the source data (patient records, laboratory results, etc)). The intensity of this verification is related to the risks of the study. Inclusion and exclusion criteria and the primary outcome measure of the study will always be checked based on a monitoring plan designed by VU Medical Centre's CRB. The monitor will also check if (S)AEs are reported properly within the time limits, as set by legislation and regulation. During the study, the independent monitor schedules four monitoring visits. The first visit is scheduled after the inclusion of the third participant, the second visit is scheduled 6 months later, the third visit is 1 year after the second visit and finally a closeout visit.

Harms

A reported side effect of sialendoscopy is postoperative swelling. Postoperative swelling usually occurs during the initial 48 hours and may last for 3–5 days after the procedure. A possible but rare complication is perforation of the salivary duct and the creation of tissue damage due to the application of excessive force. When this occurs during the procedure, the treatment will be terminated immediately. Spontaneous wound healing is expected within 1 week, usually apparent within 1–2 days. The patient will be recalled to the clinic 1 week after this AE for a follow-up. In a previous study, we showed that classic sialendoscopy is a safe method to use in patients with SS with a low number of complications.⁹

US is a safe and non-invasive imaging technique. According to the European Medicines Agency (EMA) guidelines, the most common side effects of SonoVue microbubbles injected into a vein are headache, nausea (feeling sick) and reactions at the injection site, which are seen in up to 1 in 100 patients. In the literature, a low incidence of adverse reactions to the use of sulphur



hexafluoride microbubbles as an US contrast agent for clinical applications in abdominal and superficial organs has been reported.³¹ The SonoVue microbubble has been approved in Europe and other countries for the improvement of endocardial border delineation during echocardiography and other non-cardiac applications.³² Throughout Europe, a number of serious allergic reactions with probable secondary cardiovascular problems have been reported to national and international registry authorities.^{32 33} Three of these reports included a fatal outcome soon after the administration of SonoVue in patients with severe coronary artery disease. Despite questions about the causal relationship, the EMA took precautionary measures to limit the use of SonoVue in patients with cardiac disease (www.emea.eu.int/humandocs/Humans/EPAR/SonoVue/SonoVue.htm). As a result of the EMA intervention, SonoVue is contraindicated in cardiac patients with suspected acute coronary syndrome, recent percutaneous coronary intervention, acute or chronic severe (NYHA class III/IV) heart failure or severe cardiac dysrhythmias. In a study investigating 30 222 patients undergoing US-enhanced sonography of abdominal and superficial organs, no patient died as a result of any adverse reaction.³¹ Six patients (0.020%) had adverse reactions of varying degrees, including two patients (0.007%) who had signs of early anaphylactic shock (chest tightness, palpitations, sweating, a rapid and weak pulse followed by cyanosis, a disappearing pulse and a drop in blood pressure) that improved after active resuscitation. The remaining four patients developed the following: redness and a rash on the arm above the injection site, nasal bleeding with nausea, nausea with vomiting and back pain with numbness of the lips and limbs. Symptoms in these four patients self-resolved after a period of rest. In 2009, another group reviewed all adverse effects in 352 consecutive cases treated in their echocardiographic laboratory.³⁴ During a 4-year period, 352 SonoVue contrast echocardiography studies were performed in 274 patients for a variety of reasons. One hundred and ninety-eight patients underwent only one SonoVue study, whereas 77 patients underwent multiple SonoVue studies. Mild adverse reactions, including skin erythema and mild sinus tachycardia, were seen in four patients (1.1%). Three patients were referred for left ventricular (LV) function assessment and one for exclusion of an LV thrombus. These mild reactions were present in 2 out of the 198 patients (1.0%) who received SonoVue only once, and two out of the 76 patients (2.6%) who received SonoVue twice. All four patients were successfully treated with intravenous clemastine and hydrocortisone. During the same 4-year period, an additional three patients (0.9%), who received SonoVue echocardiography for the first time, experienced a severe anaphylactic reaction.

It should be emphasised that in our study, the microbubbles will not be injected intravenously but into the ducts of salivary glands. Therefore, the microbubbles will not enter the bloodstream and we presume that the

occurrence of adverse reactions, as described below, will be more limited compared with intravenous infection. Nevertheless, an emergency plan and rescue measures for adverse reactions will be established by cooperating with the cardiology and emergency departments. Intravenous anti-allergic and anaphylactic drugs (H1 and H2 antihistamines, corticosteroids and epinephrine) will be available in the echocardiography/sialendoscopy room in addition to standard resuscitation equipment.³⁵ Patients also will be monitored for at least 30 min after the use of microbubbles. The AEs and SAEs will be monitored continuously and recorded. All AEs will be followed until they have abated, or until a stable situation has been reached. Depending on the event, follow-up may require additional tests or medical procedures as indicated, and/or referral to either a general physician or a medical specialist.

Withdrawal of individual subjects

Subjects can leave the study at any time for any reason, if they wish to do so, without consequences. The investigator can decide to withdraw a subject from the study for urgent medical reasons. Participants may withdraw from the study at any time for any reason if they wish to do so without any consequences. The investigator can decide to withdraw a subject from the study for urgent medical reasons. A patient will be withdrawn during the intervention in the rare event of perforation of the salivary duct with the creation of a passage or if it is not possible to enter the salivary duct. Patients that withdraw from the study will be replaced until T2, so that data will still be available from at least 10 participants. The study will be terminated prematurely, if more than 50% of the patients withdraw at T2 or if no more than 5 patients are willing to participate during the first year.

Compensation for harm

The investigator has insurance, which is in accordance with the legal requirements in the Netherlands (Article 7 Wet Medisch-wetenschappelijk Onderzoek met mensen/Medical Research Involving Human Subjects Act (WMO)). This insurance provides coverage for damage to research subjects through injury or death caused by the study. The insurance applies to damage that becomes apparent during the study or within 4 years after the end of the study.

ETHICS AND DISSEMINATION

The Medical Research Ethics Committee (MREC) of the Amsterdam UMC/VU Medical Centre (ID: NL68283.029.19) approved the study protocol and the study is being conducted in accordance with the Declaration of Helsinki. Any protocol amendments during the study will be submitted to the MREC and changed accordingly in the relevant registries. A written informed consent will be obtained from each patient.

The results of this study will be submitted for publication in a peer-reviewed journal, regardless of the outcome of this study, in accordance with personal data privacy and other applicable legislations and the Central Committee on Research Involving Human Subjects (Centrale Commissie Mensgebonden Onderzoek (CCMO)) statement on publication policy. The data will also be presented at national and international conferences. All collected data will be deposited in an open access digital repository in an anonymous form.

Patient and public involvement

A patient advisory group from the Nederlandse Vereniging voor Sjögren Patiënten/Dutch Society partnered with us for the design of the study, the informational material to support the intervention and review the burden of the intervention from the patient's perspective. This patient advisory group will meet on a regular basis for the duration of the study. At the end of the study, the patient advisory group will comment on the findings and will contribute to the dissemination plan.

DISCUSSION

To the best of our knowledge, this is the first study in which sialendoscopy and the use of US in combination with microbubbles in the salivary glands of SS patients will be investigated. Therefore, the aim of this study is to investigate the safety and practical applicability of CEUSS in salivary glands affected by SS.

US is an easily available, cost-effective and safe technique, without hazards from ionising radiation, which allows dynamic studies with real-time imaging during diagnostic or surgical procedures. Recently developed innovative techniques in US, such as CEUSS, have demonstrated to be more accurate in US assessment. However, US is limited in its ability to visualise the salivary ducts.^{16 17} The use of an intraductal contrast medium during US can enhance visualisation of the ductal system and parenchyma.^{17 36}

In our study, the therapeutic efficacy and the delivery and deep penetration of saline and oscillating microbubbles in the ductal system and parenchyma after sialendoscopy will be evaluated using CEUSS. This approach allows high-resolution visualisation of both the ductal system and parenchyma without exposure to radiation, since microbubbles are used as a contrast medium.^{17 36} If ductal obstructions are still present after re-infusion of microbubbles, sialendoscopy can be repeated in the same session.

Microbubbles have initially been used as diagnostic US contrast enhancers. However, the application of microbubbles in research and off-label use is growing. Currently, microbubbles are also used as drug/gene delivery vehicles, as O₂ gas carriers, for delivery of drugs across the blood-brain barrier and for therapeutic thrombolytic purposes.^{37 38} In our current and subsequent studies, the therapeutic possibilities for removal of ductal obstructions

will be further investigated. If successful, we plan in subsequent studies to combine microbubbles with therapeutic agents, and aim to enhance drug delivery to the salivary glands and improve outcomes in patients with SS.

Although the treatment described in the current study (ie, dissolution of strictures and occlusions of the glandular ducts using sialendoscopy) is technically a symptomatic solution, we have provided evidence that sialendoscopy is able to increase saliva flow significantly,⁹⁻¹¹ reducing the burden of the patient with SS and increasing his/her quality of life considerably. The current project has the added value over normal sialendoscopy that it encompasses non-invasive intraoperative visualisation and diagnostic imaging without radiation exposure of the patient, and we hypothesise that this real-time evaluation of the dissolution of ductal occlusions may enhance the success of our sialendoscopic treatment. Also, solutions for severe dry mouth are currently an unmet need, which could be addressed by CEUSS in a large cohort of patient with SS worldwide.

Author affiliations

¹Department of Oral and Maxillofacial Surgery / Oral Pathology, Amsterdam University Medical Center (Amsterdam UMC, Location VUmc) and Academic Centre for Dentistry Amsterdam (ACTA), Vrije Universiteit Amsterdam, Amsterdam, The Netherlands

²Department of Radiology and Nuclear Medicine, Amsterdam University Medical Center (Amsterdam UMC, Location VUmc), Vrije Universiteit Amsterdam, Amsterdam, The Netherlands

³Department of Cardiology, Amsterdam University Medical Center (Amsterdam UMC, Location VUmc), Amsterdam, The Netherlands

⁴Department of Oral Biochemistry, Academic Centre for Dentistry Amsterdam (ACTA), Amsterdam, The Netherlands

⁵Department of Oral and Maxillofacial Diagnostic Sciences, Division of Oral Medicine, University of Florida College of Dentistry, Gainesville, Florida, USA

⁶Department of Biochemistry, MU Bond Life Sciences Center, University of Missouri, Columbia, Missouri, USA

⁷Department of Clinical Pharmacology and Pharmacy, Amsterdam University Medical Center (Amsterdam UMC, Location VUmc), Amsterdam, The Netherlands

⁸Department of Oral and Maxillofacial Surgery, University Medical Center Groningen, University of Groningen, Groningen, The Netherlands

Contributors KHK, MH and DJJ are the project leaders and wrote the manuscript. KHK, MH, JB, OK, TF, HB, SC, GW, IB, AV and DJJ conceived, planned and designed the project. JB, OK, TF, HB, SC, GW, IB and AV critically revised the article and all authors approved the final version for submission.

Funding The authors have not declared a specific grant for this research from any funding agency in the public, commercial or not-for-profit sectors.

Competing interests None declared.

Patient and public involvement Patients and/or the public were involved in the design, or conduct, or reporting, or dissemination plans of this research. Refer to the Methods section for further details.

Patient consent for publication Not required.

Provenance and peer review Not commissioned; externally peer reviewed.

Open access This is an open access article distributed in accordance with the Creative Commons Attribution Non Commercial (CC BY-NC 4.0) license, which permits others to distribute, remix, adapt, build upon this work non-commercially, and license their derivative works on different terms, provided the original work is properly cited, appropriate credit is given, any changes made indicated, and the use is non-commercial. See: <http://creativecommons.org/licenses/by-nc/4.0/>.

ORCID iDs

K Hakki Karagozlu <http://orcid.org/0000-0002-6605-6889>

REFERENCES

- 1 Kroese FGM, Abdulhad WH, Haacke E, *et al.* B-Cell hyperactivity in primary Sjögren's syndrome. *Expert Rev Clin Immunol* 2014;10:483–99.
- 2 Qin B, Wang J, Yang Z, *et al.* Epidemiology of primary Sjögren's syndrome: a systematic review and meta-analysis. *Ann Rheum Dis* 2015;74:1983–9.
- 3 Mariette X, Criswell LA. Primary Sjögren's syndrome. *N Engl J Med* 2018;378:931–9.
- 4 Pijpe J, Kalk WWI, Bootsma H, *et al.* Progression of salivary gland dysfunction in patients with Sjogren's syndrome. *Ann Rheum Dis* 2007;66:107–12.
- 5 Fox RI. Sjögren's syndrome. *Lancet* 2005;366:321–31.
- 6 Shacham R, Puterman MB, Ohana N, *et al.* Endoscopic treatment of salivary glands affected by autoimmune diseases. *J Oral Maxillofac Surg* 2011;69:476–81.
- 7 De Luca R, Trodella M, Vicidomini A, *et al.* Endoscopic management of salivary gland obstructive diseases in patients with Sjögren's syndrome. *J Craniomaxillofac Surg* 2015;43:1643–9.
- 8 Koch M, Iro H, Zenk J. Role of sialoscopy in the treatment of Stensen's duct strictures. *Ann Otol Rhinol Laryngol* 2008;117:271–8.
- 9 Karagozoglu KH, De Visscher JG, Forouzanfar T, *et al.* Complications of sialendoscopy in patients with Sjögren syndrome. *J Oral Maxillofac Surg* 2017;75:978–83.
- 10 Jager DJ, Karagozoglu KH, Maarse F, *et al.* Sialendoscopy of salivary glands affected by Sjögren syndrome: a randomized controlled pilot study. *J Oral Maxillofac Surg* 2016;74:1167–74.
- 11 Karagozoglu KH, Vissink A, Forouzanfar T, *et al.* Sialendoscopy enhances salivary gland function in Sjögren's syndrome: a 6-month follow-up, randomised and controlled, single blind study. *Ann Rheum Dis* 2018;77:1025–31.
- 12 Slikkerveer J, Kleijn SA, Appelman Y, *et al.* Ultrasound enhanced prehospital thrombolysis using microbubbles infusion in patients with acute ST elevation myocardial infarction: pilot of the Sonolysis study. *Ultrasound Med Biol* 2012;38:247–52.
- 13 Mathias W, Tsutsui JM, Tavares BG, *et al.* Diagnostic ultrasound impulses improve microvascular flow in patients with STEMI receiving intravenous microbubbles. *J Am Coll Cardiol* 2016;67:2506–15.
- 14 Ebben HP, Nederhoed JH, Lely RJ, *et al.* Microbubbles and UltraSound-accelerated thrombolysis (must) for peripheral arterial occlusions: protocol for a phase II single-arm trial. *BMJ Open* 2017;7:e014365.
- 15 Slikkerveer J, Juffermans LJM, van Royen N, *et al.* Therapeutic application of contrast ultrasound in ST elevation myocardial infarction: role in coronary thrombolysis and microvascular obstruction. *Eur Heart J* 2019;8:45–53.
- 16 David E, Cantisani V, De Vincentiis M, *et al.* Contrast-enhanced ultrasound in the evaluation of parotid gland lesions: an update of the literature. *Ultrasound* 2016;24:104–10.
- 17 Zengel P, Berghaus A, Weiler C, *et al.* Intraductally applied contrast-enhanced ultrasound (IA-CEUS) for evaluating obstructive disease and secretory dysfunction of the salivary glands. *Eur Radiol* 2011;21:1339–48.
- 18 Chan A-W, Tetzlaff JM, Gotzsche PC, *et al.* SPIRIT 2013 explanation and elaboration: guidance for protocols of clinical trials. *BMJ* 2013;346:e7586.
- 19 Shiboski CH, Shiboski SC, Seror R, *et al.* 2016 American College of Rheumatology/European League against rheumatism classification criteria for primary Sjögren's syndrome. *Ann Rheum Dis* 2017;76:9–16.
- 20 Luers JC, Ortmann M, Beutner D, *et al.* Intraductal pressure during sialendoscopy. *J Laryngol Otol* 2014;128:897–901.
- 21 Osailan SM, Pramanik R, Shirlaw P, *et al.* Clinical assessment of oral dryness: development of a scoring system related to salivary flow and mucosal wetness. *Oral Surg Oral Med Oral Pathol Oral Radiol* 2012;114:597–603.
- 22 Jager DHJ, Bots CP, Forouzanfar T, *et al.* Clinical oral dryness score: evaluation of a new screening method for oral dryness. *Odontology* 2018;106:439–44.
- 23 van Lankveld W, van 't Pad Bosch P, van de Putte L, *et al.* [Pain in rheumatoid arthritis measured with the visual analogue scale and the Dutch version of the McGill Pain Questionnaire]. *Ned Tijdschr Geneesk* 1992;136:1166–70.
- 24 Thomson WM, Chalmers JM, Spencer AJ, *et al.* The xerostomia inventory: a multi-item approach to measuring dry mouth. *Community Dent Health* 1999;16:12–17.
- 25 Seror R, Bootsma H, Saraux A, *et al.* Defining disease activity states and clinically meaningful improvement in primary Sjögren's syndrome with EULAR primary Sjögren's syndrome disease activity (ESSDAI) and patient-reported indexes (ESSPRI). *Ann Rheum Dis* 2016;75:382–9.
- 26 Meiners PM, Arends S, Brouwer E, *et al.* Responsiveness of disease activity indices ESSPRI and ESSDAI in patients with primary Sjögren's syndrome treated with rituximab. *Ann Rheum Dis* 2012;71:1297–302.
- 27 Hočevar A, Rainer S, Rozman B, *et al.* Ultrasonographic changes of major salivary glands in primary Sjögren's syndrome. evaluation of a novel scoring system. *Eur J Radiol* 2007;63:379–83.
- 28 Navazesh M. Methods for collecting saliva. *Ann N Y Acad Sci* 1993;694:72–7.
- 29 Kalk WW, Vissink A, Spijkervet FK, *et al.* Sialometry and sialochemistry: diagnostic tools for Sjögren's syndrome. *Ann Rheum Dis* 2001;60:1110–6.
- 30 Silletti E, Vingerhoeds MH, Norde W, *et al.* Complex formation in mixtures of lysozyme-stabilized emulsions and human saliva. *J Colloid Interface Sci* 2007;313:485–93.
- 31 Tang C, Fang K, Guo Y, *et al.* Safety of sulfur hexafluoride microbubbles in sonography of abdominal and superficial organs: retrospective analysis of 30,222 cases. *J Ultrasound Med* 2017;36:531–8.
- 32 de Groot MCH, van Zwieten-Boot BJ, van Grootheest AC. [Severe adverse reactions after the use of sulphur hexafluoride (SonoVue) as an ultrasonographic contrast agent]. *Ned Tijdschr Geneesk* 2004;148:1887–8.
- 33 Dijkmans PA, Visser CA, Kamp O. Adverse reactions to ultrasound contrast agents: is the risk worth the benefit? *Eur J Echocardiogr* 2005;6:363–6.
- 34 Geleijnse ML, Nemes A, Vletter WB, *et al.* Adverse reactions after the use of sulphur hexafluoride (SonoVue) echo contrast agent. *J Cardiovasc Med* 2009;10:75–7.
- 35 Katayama H, Yamaguchi K, Kozuka T, *et al.* Adverse reactions to ionic and nonionic contrast media. A report from the Japanese Committee on the safety of contrast media. *Radiology* 1990;175:621–8.
- 36 Oh SH, Kang JH, Choi YJ, *et al.* Ultrasound-Guided sialo-irrigation with a saline-air mixture as the contrast medium. *Oral Radiol* 2019;35:84–9.
- 37 Upadhyay A, Dalvi SV. Microbubble formulations: synthesis, stability, modeling and biomedical applications. *Ultrasound Med Biol* 2019;45:301–43.
- 38 Appis AW, Tracy MJ, Feinstein SB, *et al.* Update on the safety and efficacy of commercial ultrasound contrast agents in cardiac applications. *Echo Res Pract* 2015;2:R55–62.