

BMJ Open Construct validity of a clinically correlated knee osteoarthritis ultrasonographic scale: a cross-sectional observational study

Mohamed Mortada , Ghada A Dawa, Youmna A Amer

To cite: Mortada M, Dawa GA, Amer YA. Construct validity of a clinically correlated knee osteoarthritis ultrasonographic scale: a cross-sectional observational study. *BMJ Open* 2021;**11**:e048444. doi:10.1136/bmjopen-2020-048444

► Prepublication history for this paper is available online. To view these files, please visit the journal online (<http://dx.doi.org/10.1136/bmjopen-2020-048444>).

Received 25 December 2020
Accepted 11 November 2021

ABSTRACT

Objectives To assess the validity of a novel ultrasonographic scale for knee osteoarthritis (KOA) and its relation with the degree of pain and clinical features.

Design A cross-sectional observational study including 245 patients with knee pain who fulfilled the American College of Rheumatology criteria for KOA. All patients were subjected to clinical assessment Western Ontario and McMaster Universities Index of Osteoarthritis (WOMAC) scale, global visual analogue scale (VAS) and functional assessment through the use of Health Assessment Questionnaire-II (HAQ-II). Ultrasonographic assessment was conducted following ZAGAZIG scale comprising five domains: one for degenerative features (one-third of total score) and the other four for inflammatory features (two-thirds of score).

Results There were positive correlations between ZAGAZIG score and all WOMAC subscales (pain, stiffness and function) ($r=0.71$, $p=0.00$; $r=0.62$, $p=0.00$; $r=0.70$, $p=0.00$, respectively).

Moreover, there was a strong positive correlation between ZAGAZIG scale and both VAS and HAQ-II ($r=0.82$, $p=0.00$ and $r=0.67$, $p=0.00$). At cut-off point of >5, total US score distinguishes between patients with KOA with no or mild pain and those with moderate pain (87.2 sensitivity and 87.2 specificity). At cut-off point of 7, total score of ZAGAZIG scale distinguishes between patients with KOA with moderate pain and those with severe pain (94.5 sensitivity and 42.5 specificity).

Conclusion ZAGAZIG scale constitutes a validated tool for KOA assessment. ZAGAZIG scale correlated with WOMAC subscales (pain, stiffness and function), VAS and HAQ.

INTRODUCTION

The knee is one of the most common joints involved in osteoarthritis (OA). Symptomatic knee OA (KOA) occurs in 10% men and 13% women aged 60 years or older. The number of people affected with symptomatic OA is likely to increase because of the ageing of the population and the obesity epidemic.¹ OA has been thought to be cartilage driven for long time, but recent studies demonstrated an integrated role of subchondral bone and synovial membrane.²

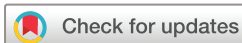OA is not only a disease characterised by loss of cartilage as a result of mechanical loading,

Strengths and limitations of this study

- This study aims at assessing the validity of a novel ultrasonographic scale (ZAGAZIG scale) for knee osteoarthritis and its relation with the degree of pain and clinical features.
- Convergent and discriminative validity will be tested.
- Inter-readers' reliability of each item of the scale and the total score will be tested.
- Cut-off values that discriminate between mild, moderate and severe pain will be detected.
- KOA is very prevalent disease. This study was performed on 245 patients, but still a multicentre larger study is needed.

but also a condition affecting all the tissues in the joint, causing detectable changes in tissue architecture, its metabolism, and function.³ All these changes are mediated by a complex and not yet fully researched interplay of proinflammatory and anti-inflammatory cytokines, chemokines, growth factors and adipokines.⁴ Another key aspect of disease progression is the epigenome that regulates all the genetic expression through DNA methylation, histone modifications and mRNA interference.⁵ Dysregulation of local turnover and changes in the repairing process involve the cartilage and different articular tissues. This results in global joint involvement.⁶ There is progressive loss of the articular cartilage, with meniscal protrusion and hypertrophy of the subchondral bone, joint margin and capsule.⁷ Synovitis, which is considered as non-destructive and non-aggressive with a typical episodic course, commonly occurs and is usually characterised by synovial proliferation, joint effusion, bursitis and popliteal cyst.^{8–11} Osteophytes, which are bony projections in the marginal and central regions of the knee joint space, are seen later in the disease.^{12 13}

Understanding the cause of pain in KOA is still a challenge. The pain is not only caused by bone and cartilage pathology. Knee pain



© Author(s) (or their employer(s)) 2021. Re-use permitted under CC BY-NC. No commercial re-use. See rights and permissions. Published by BMJ.

Rheumatology, Zagazig University, Zagazig, Egypt

Correspondence to

Dr Mohamed Mortada;
M_a_Mortada@yahoo.com

in OA is multifactorial, mechanical, inflammatory, structural, bone-related, psychological and neurological factors play a role in the process resulting in painful KOA.²

In clinical practice, severity of KOA is primarily assessed through the use of conventional radiography as described by the Kellgren-Lawrence grading.¹⁴ However, structural alterations visible on radiographs such as bone abnormalities and joint space narrowing are known to appear only at relatively late stages of the disease.¹⁵

The limitation of radiography is its inability to visualise the hyaline cartilage and periarticular soft tissues and to assess inflammation. In addition, it has very low sensitivity in demonstrating minimal cartilage involvement in the early stages of the disease.¹⁶

To date, MRI is considered the most accurate imaging modality in the assessment of KOA for highlighting OA structural and inflammatory joint and periarticular changes.¹⁷ Despite its high sensitivity, it is limited by its high cost and contraindications in patients with metal implants. MRI is not usually used as an initial imaging technique for KOA. Its prohibitive cost and inaccessibility, however, limit its use.^{16–19}

Recently, musculoskeletal ultrasound (MSUS) is emerging as a new imaging tool that is non-invasive, safe and relatively inexpensive and can create static and dynamic images. It is a real-time method that offers data for immediate correlations between image findings and clinical symptoms and signs of pathology.^{19–21} It can provide clinically useful information on a wide range of pathological conditions affecting components of the knee joint, such as the tendons, ligaments, muscles, synovial space, articular cartilage and surrounding soft tissues.²² MSUS can detect inflammatory changes, including synovial effusion, synovial hypertrophy and increased pathological vascularisation within the synovial structures, which is reflective of active inflammation.^{17 23 24} There has been a growing interest in determining the sources of pain among ultrasound findings in patients with KOA. Ultrasonography can detect various features of OA. Some of these features may be considered as signs of joint degeneration (cartilage degeneration, tears of menisci and osteophytes), and other features may be considered as inflammatory features (effusion, synovitis, bursitis and Backer cyst (BC)).¹⁰

Although degenerative features may contribute as a source of pain in KOA, these are relatively slowly changed features and not expected to vary with the change of symptoms. Meanwhile, inflammatory features may vary

from day to day and hence may be correlated with clinical features.

Subsequently, the association of ultrasonographic features with clinical pictures indicated discrepancies with some features correlated with other features not correlated with clinical picture.^{6 18 25–32}

Up till now, there is no composite score directly correlated with clinical features.

The aim of the current study is to assess the validity of a novel ultrasonographic scale for KOA and its relation with the degree of pain and clinical features.

METHODS

A cross-sectional observational study included 245 patients with knee pain who fulfilled the American College of Rheumatology (ACR) criteria for KOA.³³ Patients were randomly recruited from Zagazig Rheumatology and Rehabilitation outpatient clinic from November 2018 to May 2019. The inclusion criterion was the fulfilment of the clinical or the radiological criteria for KOA of the ACR. Exclusion criteria were (1) secondary KOA and (2) a history of knee surgery. It was not possible to involve patients or the public in the design, or conduct, or reporting, or dissemination plans of our research.

All patients were subjected to clinical assessment in the form of Western Ontario and McMaster Universities Index of Osteoarthritis (WOMAC)³⁴ and visual analog scale (VAS) through the use of the Universal Pain Assessment Tool (UPAT).³⁵

Functional assessment was carried out using Health Assessment Questionnaire-II (HAQ-II).³⁶

Ultrasonography

Knee ultrasonography was performed following the European League Against Rheumatism guidelines³⁷ by a rheumatologist, who was experienced in MSUS and blinded to the clinical and radiographic evaluations. All patients were examined using B-mode (grey scale) real-time MSUS (LOGIC E10 GE, Healthcare) interfaced with a 5–13 MHz linear array transducer. Ultrasonographic assessment of activity was conducted as per ZAGAZIG scale (ZAGAZIG was derived from the name of the university) and included the following five domains:

(I) Severity of KOA: according to severity scale published by Mortada *et al* 2016,³⁸ severity of KOA depended on the shape of distal femoral osteophytes. The scale consisted of five grades (0–4) with grade 2 having two subgrades A and

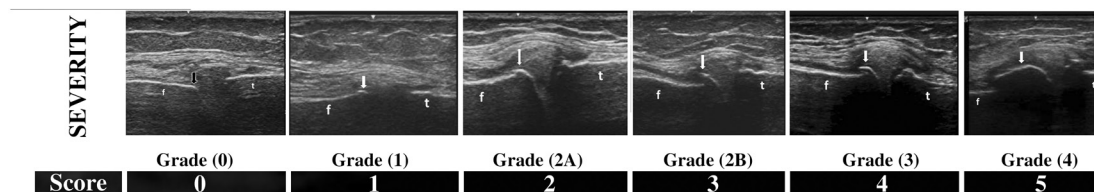

Figure 1 Different grades of severity of knee osteoarthritis by ultrasonography according to the shape of medial femoral osteophytes. White arrow, medial femoral osteophyte. f; femur, t; tibia.

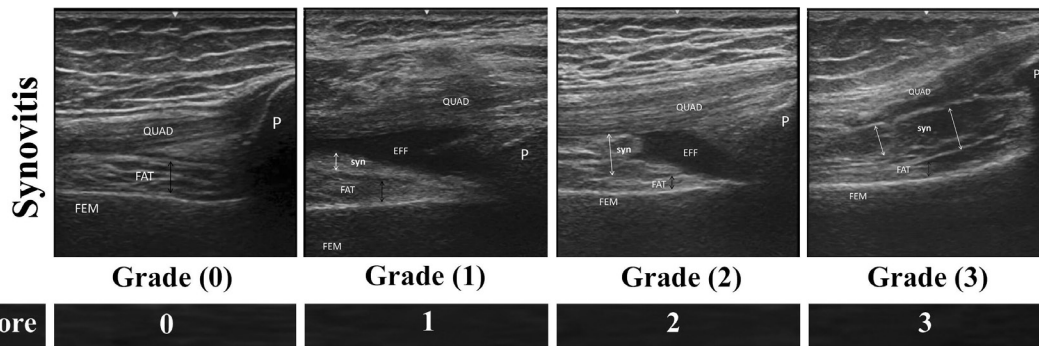


Figure 2 Grades of synovitis (grey scale) at suprapatellar pouch. Quad; quadriceps tendons, P; patella, Fem; femur, Fat; fat bad (double headed black arrow), EFF; effusion, syn; synovitis (double headed white arrow).

B, where grade 0 denoted no OA and grade 4 denoted the most advanced grade of KOA (scores from 0 to 5), as presented in [figure 1](#). The patients were positioned supine with their knees in full extension. The knees were scanned longitudinally in the coronal plane at the level of the knee joint, where the medial collateral ligament and the body of the medial meniscus could be detected. The probe was moved in the coronal plane from superior to inferior in order to detect osteophytes that were defined as cortical protrusions. The distal medial osteophytes were graded independently of the number, size and location of other osteophytes in the same joint. If there were different shapes of the osteophyte during scanning, the most advanced one was considered according to the scale.

(II) Effusion: it was detected as an abnormal anechoic (but it sometimes may be hypoechoic relative to subdermal fat) intra-articular material that is displaceable and compressible and that does not exhibit a Doppler signal.

Four grades (with scores grading from 0 to 3) were as follows:

- ▶ 0: no effusion.
- ▶ 1: mild effusion with joint capsule distension that is parallel to femur bone.
- ▶ 2: moderate effusion with straight joint capsule distension.
- ▶ 3: severe effusion with convex joint capsule distension.

The knees were scanned longitudinally in the suprapatellar, medial and lateral recesses. The most advanced grade of effusion in any of the three positions was considered ([figure 2](#)).

(III) Synovitis: it was detected as an abnormal hypoechoic (relative to subdermal fat, but it sometimes may be isoechoic or hyperechoic) intra-articular tissue that is non-displaceable and poorly compressible and that may exhibit a Doppler signal.³⁹

The knees were scanned in both modes (grey scale and power Doppler) longitudinally in the suprapatellar, medial and lateral recesses. Synovitis was graded on grey scale separately in the three positions with the most advanced grade of synovial proliferation in any of the three positions being considered ([figure 3](#)).

Four grades of grey scale synovitis (with scores grading from 0 to 3) were as follows:

- ▶ 0: no synovitis.
- ▶ 1: mild synovitis with joint capsule distension that is parallel to femur bone.
- ▶ 2: moderate synovitis with straight joint capsule distension.
- ▶ 3: severe synovitis with convex joint capsule distension.

(IV) Pes anserine tendonitis/bursitis (PAB): PAB has three grades (0–2): normal, mild inflammation and severe inflammation. The knee was bent at a 5°–10° angle, and ultrasound imaging was performed on the medial aspect of the knee. Grading of PAB inflammation was done as follows: grade 0, normal hyperechoic picture of pes anserine tendon without tendonitis or bursitis; grade 1, mild hypoechoogenicity and/or mild swelling or mild loss of fibrillar pattern of the pes anserine tendon and/or mild anechoic effusion related to the tendons; grade 2, marked hypoechoogenicity and/or large swelling or a marked loss of the pes anserine

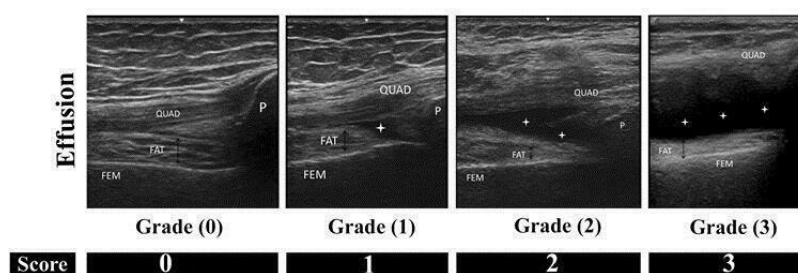


Figure 3 Grades of effusion (grey scale) at suprapatellar pouch. Quad; quadriceps tendons, P; patella, Fem; femur, Fat; fat bad (double headed black arrow), Star; effusion.

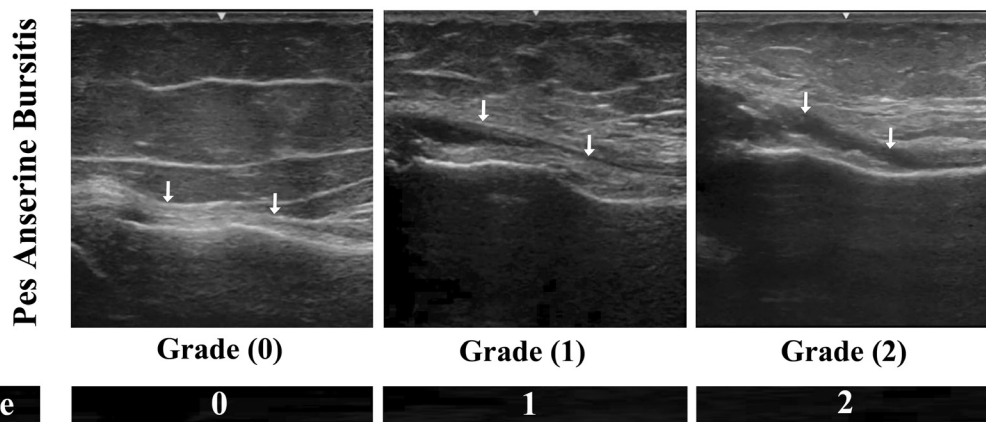


Figure 4 Grades of Pes anserine bursitis/tendonitis. White arrows Pes anserine tendon.

tendon and/or marked anechoic effusion related to the tendon (figure 4).

(V) *Baker's cyst*: ultrasonographic assessment for the presence and absence of a BC was performed from the back of the knee with the patient prone and knee extended by examining the posteromedial aspect of the knee. BC appears as a thin hypoechoic space delimited by echogenic borders corresponding to the tissue–fluid interface anatomically present between the medial head of the gastrocnemius and the semimembranosus muscles. Three grades (0–2) were considered: grade 0: normal or no cyst; grade 1: small cyst with its cross-sectional diameter being less than the cross-sectional diameter of the medial head of gastrocnemius muscle; grade 2: large cyst with its cross-sectional diameter being less than the cross-sectional diameter of the medial head of the gastrocnemius (figure 5).

The scores of all domains ranged from 0 to 15 and were summarised in figure 6.

In order to detect inter-readers' reliability, each patient was examined by two ultrasonographers (MAM and YAA) on the same day. The images and grades detected by each sonographer were recorded separately and delivered to another member of the research team (GAD). The sonographers were blinded to the results of other assessments.

In order to detect intra-reader reliability, ultrasonographic examinations of 50 patients were repeated by the same ultrasonographer 2 days after the first examination.

Statistical analysis

Continuous data were presented as means with SDs or medians and IQRs, based on their distribution (evaluated through the Kolmogorov–Smirnov test). Categorical data were presented as proportions. Demographic and clinical measures were compared through the use of the Mann–Whitney U test for continuous variables and χ^2 analysis for discontinuous variables. P values below 0.05 were regarded as statistically significant. The construct validity of the scale was investigated in two ways. First, the convergent validity of the scale was explored. Convergent validity examines the extent to which a particular measurement relates to other scales that are believed to assess the same construct. In the absence of a true 'gold standard' against which to assess criterion validity of the scale, this scale was compared with commonly used external measurements likely to reflect the impact of KOA. Thus, the correlation between the scale and WOMAC scale, HAQ-II and the VAS using the UPAT was measured. Spearman's correlation coefficient was used for testing the convergent validity of the questionnaire. Second, the receiver

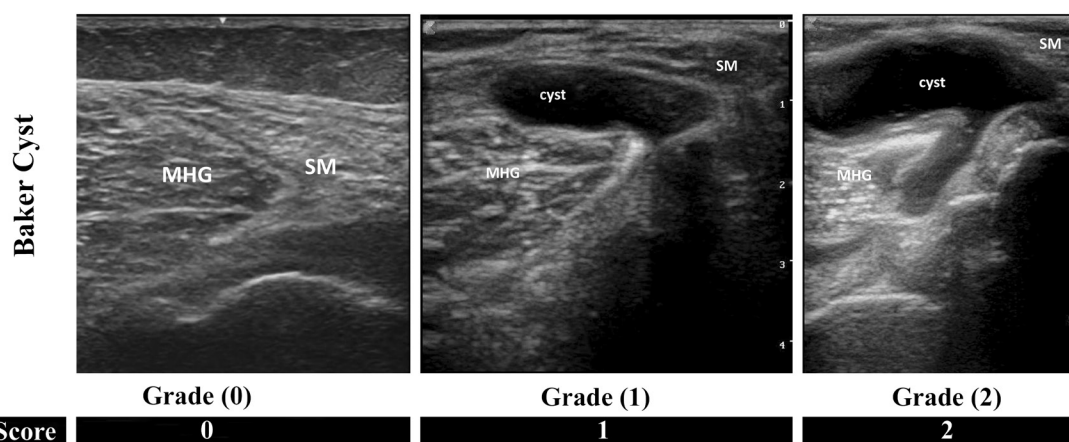


Figure 5 Grades of Baker cyst. MHG, medial head of gastrocnemius muscle; SM, semimembranosus tendon; cyst, Baker cyst.

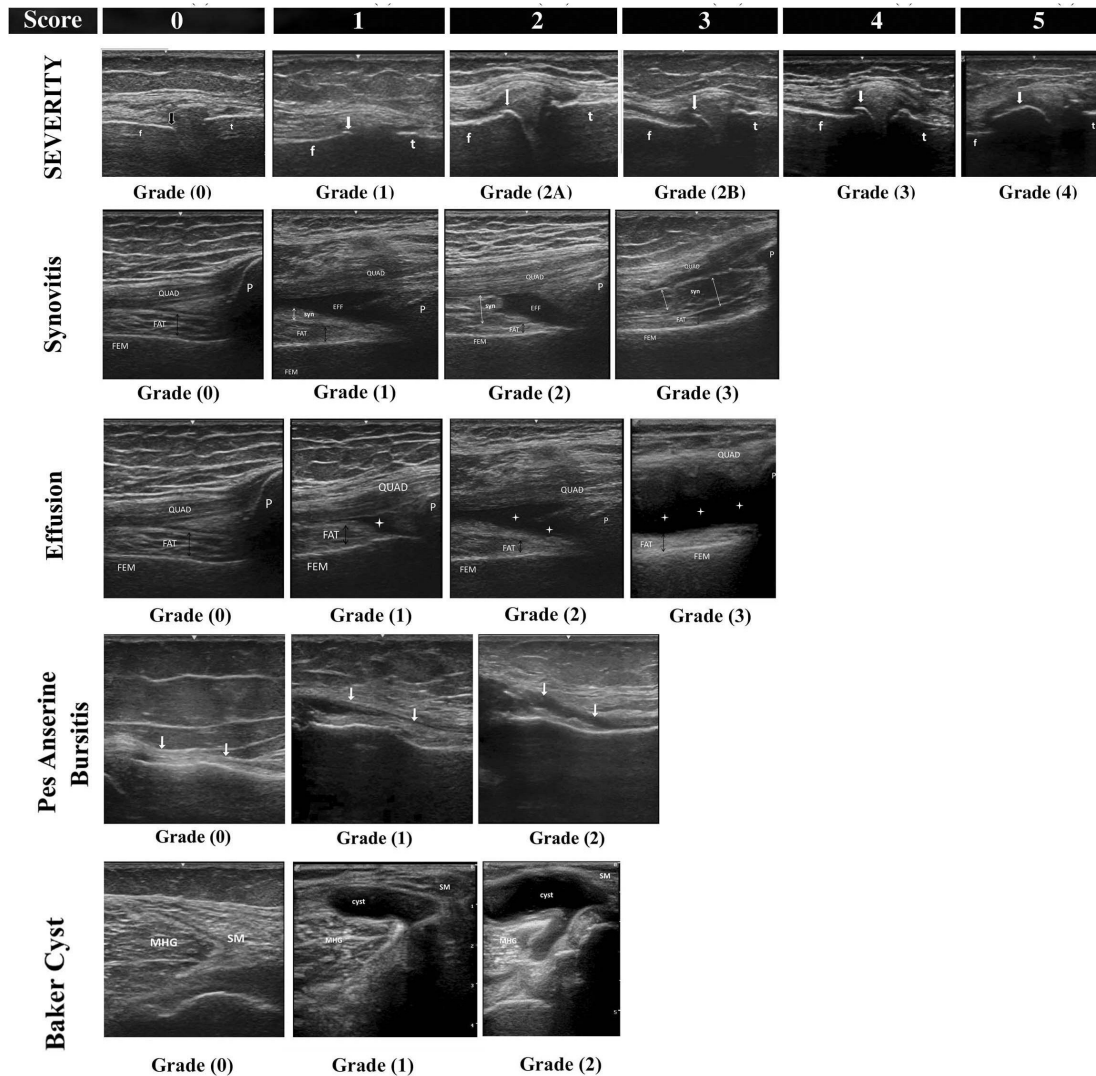


Figure 6 Domains of ZAGAZIG ultrasonographic scale for knee osteoarthritis with its corresponding scores. f (Fem); femur, t; tibia, P; patella, Fat; fat bad (double headed black arrow), EFF(star); effusion, syn; synovitis (double headed white arrow).

operating characteristic (ROC) curve analysis was used in order to explore the discriminative accuracy of the scores, to distinguish patients with mild, moderate and severe pain. The UPAT was applied as an external criterion. ROC curves were created through plotting the true-positive proportion (sensitivity) versus the false-positive proportion (100-specificity) in order to discriminate between inactive and active patients for multiple cut-off points. The area under the ROC curve (AUC) was calculated in order to quantify the discriminative accuracy. Values for the AUC-ROC from 0.7 to 0.8 indicate reasonable discrimination, whereas values exceeding 0.8 indicate good discrimination. We defined the best cut-off value as the value with the highest accuracy that maximises Youden's index. Youden's index is a single statistic that captures the performance of a dichotomous diagnostic test. The data were analysed via the SPSS V.11.0 (SPSS) and the MedCalc V.16.0 (MedCalc Software bvba, Ostend, Belgium) for Windows XP.

RESULTS

This study included 245 patients with KOA, most of them 221 (90.2%) were women. The ages of patients ranged from 47 years to 63 years with a mean body mass index (31.3 ± 6.7). WOMAC subscales (pain, stiffness and function) (mean \pm SD) were (5.1 ± 4.3 , 1.7 ± 1.9 and 12.4 ± 10.9), respectively, with total WOMAC score was 19.3 ± 15.9 . VAS using UPAT was 5.3 ± 1.2 (mean \pm SD). HAQ-II was 7.7 ± 3.1 (mean \pm SD).

Figure 7 shows prevalence of different ultrasonographic parameters in the studied group of patients with KOA.

As regards to grades of severity of KOA as detected by ultrasonography, the frequency of the different grades of severity were as follows (grade 1: 0.48%, grade 2a: 4.5%, grade 2b: 15.9%, grade 3: 41.9%, grade 4: 27.8%) figure 8.

Discriminate validity

The ROC curves to discriminate the ability of the score to distinguish between patients with KOA with no or mild pain to moderate pain were good with an AUC of

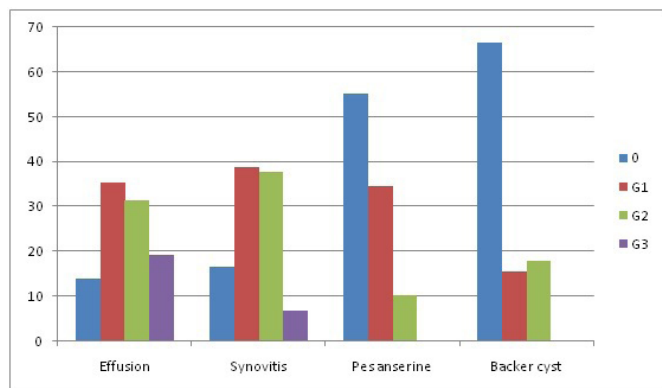


Figure 7 Prevalence of different ultrasonographic parameters according to ZAGZIG scale in patients with knee osteoarthritis.

0.54 (95% CI 0.40 to 0.68; $p < 0.0001$). The ROC curve achieved a maximum Youden's index at 5, where sensitivity was 87.2% and specificity 87.2% (figure 9A).

The ROC curves to discriminate the ability of the score to distinguish between patients with KOA with moderate pain to severe pain were very good with an AUC of 0.88 (95% CI 0.84 to 0.93; $p < 0.0001$). The ROC curve achieved a maximum Youden's index at 7, where sensitivity was 94.5%, specificity 42.5, positive prediction value 61.5% and negative prediction value 88.9% (figure 9B).

Convergent validity

The proposed US scale was highly significantly correlated with age ($r = 0.36$, $p = 0.00$), VAS ($r = 0.73$, $p = 0.001$), HAQ-II ($r = 0.67$, $p = 0.001$), and WOMAC pain subscale ($r = 0.3$, $p = 0.03$), stiffness subscale ($r = 0.23$, $p = 0.00$), function subscale ($r = 0.40$, $p = 0.01$), and total WOMAC ($r = 0.70$, $p = 0.00$).

According to universal pain assessment there was 22 patients had no to mild pain, 113 patients had moderate pain and 110 patients had severe pain. There was strong statistically significant association ($p \geq 0.05$) between universal pain assessment and proposed US score.

The inter-readers reliability of US as regard to osteophyte grades was very good (agreement: 70.8%, difference: 29.16%, kappa: 0.95, $p \leq 0.001$), as regard to effusion was very good (agreement: 100%, kappa: 1, $p \leq 0.001$),

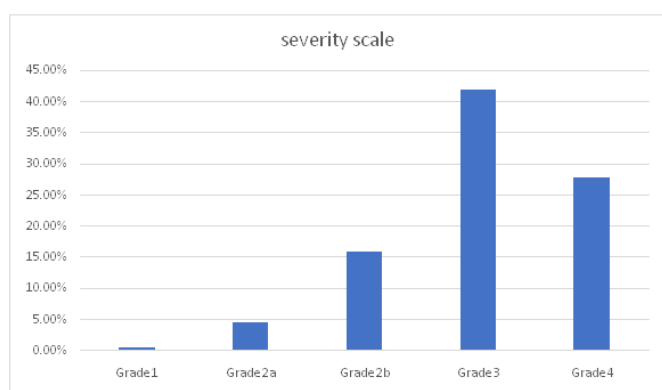


Figure 8 The frequency of different grades of severity scale.

as regard to baker cyst was good (agreement: 91.6%, difference: 8.33%, kappa: 0.77, $p \leq 0.001$) but as regard to Pes anserine bursitis. The inter-readers reliability was fair (agreement: 66.6%, difference: 33.3%, kappa: 0.29, $p = 0.07$) and for total score was very good (agreement: 82.8%, difference: 13.5%, kappa: 0.81, $p \leq 0.001$). The intrareader reliability for the two ultrasonographers was very good, for the first reader (MAM), (agreement: 89.4%, difference: 12.4%, kappa: 0.87, $p \leq 0.001$), and the second reader (YAA), (agreement: 86.5%, difference: 13.5%, kappa: 0.82, $p \leq 0.001$).

DISCUSSION

Ultrasonography is widely available in rheumatology clinics, and its use in daily practice has become a routine. Radiography is still the cornerstone in diagnosing KOA, and it can detect four grades of severity of KOA.¹⁴ Ultrasonography has the ability to detect different features of degenerative and inflammatory lesions associated with KOA.¹⁹ Furthermore, US has proved to detect the same grades of severity of KOA detected by radiography.³⁶ Both X-ray and ultrasonography-detected grades are not correlated with clinical picture in the form of symptoms (pain and limitation of range of motion) and function (HAQs).^{30–32}

Development of a symptom-related grading scale for KOA might be of many clinical benefits as it will give an objective evidence of increase or decrease in the activity of KOA. In addition, this may guide clinical decisions.

This study seeks to assess the correlation between a novel ultrasonographic scale and clinical parameters for KOA.

Traditionally, the source of pain and dysfunction related to KOA is considered a result of a combination of degenerative and inflammatory lesions.³⁷

We previously present a grading scale for the severity of KOA in which medial femoral osteophyte proved to be a representative to degenerative features and hence can be used alone for detecting the different degenerative changes of KOA including cartilage degeneration.³⁸

Consequently, the present scale for KOA is composed of five domains with total score being 15. One domain (severity of KOA) may be considered as a degenerative feature with a score ranging from 0 to 5; that is, it represents one-third of the total score. The other four domains (effusion, synovitis, PAB and Baker cyst), which have two-thirds of the total score (0–10), may be considered as inflammatory lesions.

In the present study, the correlations between ZAGAZIG score and all WOMAC subscales (pain, stiffness, and function) were highly positive.

Moreover, there was a strong positive correlation between ZAGAZIG scale and functional status that was assessed by HAQ-II.

This is in contrast to previous studies^{30–32} that failed to find any direct correlation between the radiographic/

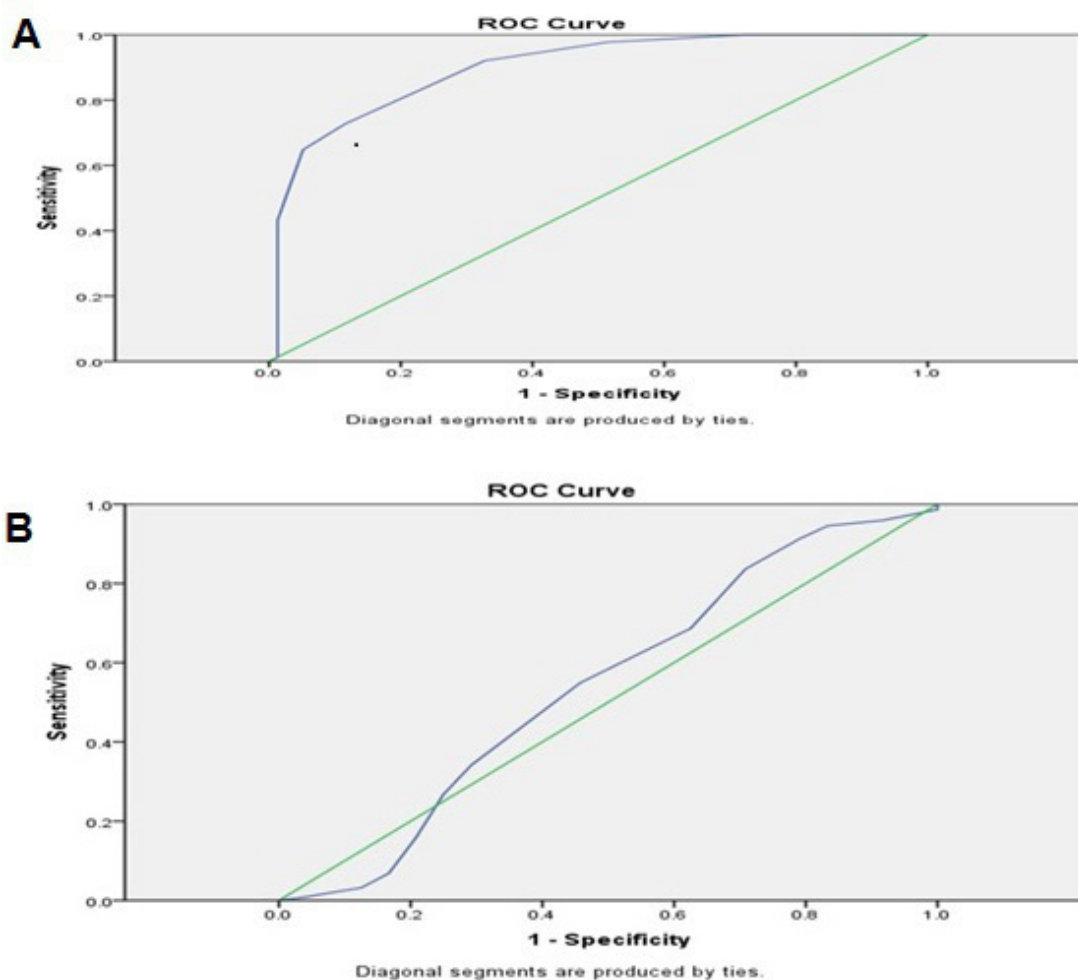


Figure 9 (A) The receiver operating characteristic (ROC) curves to discriminate the ability of the score to distinguish between patients with knee osteoarthritis with no or mild pain to moderate pain. (B) The ROC curves to discriminate the ability of the score to distinguish between patients with knee osteoarthritis with moderate pain to severe pain.

ultrasonographic detected grades of KOA and clinical parameters in the form of pain or function.

Another essential point is that ZAGAZIG scale gives different cut-off points for various levels or degrees of pain (mild, moderate and severe). Taking into consideration that the principles of OA treatment are to alleviate pain and stiffness as well as maintain function, the presence of points for mild levels or absence of symptoms may be considered an objective target of therapy.

To the best of the authors' knowledge, ZAGAZIG scale is the first ultrasonographic scale that correlated with clinical parameters.

Further longitudinal studies are needed to investigate the response to therapy of KOA assessed with ZAGAZIG scale.

The current study has some limitations. Although this study was performed on 245 patients, KOA is a very prevalent disease, so a multicentre larger study is still needed. Moreover, most of the patients included in this study were females.

To sum up, ZAGAZIG scale is composed of five domains: one for degenerative features (one-third of total score)

and the other four domains for inflammatory features (two-thirds of score). The current study confirmed that ZAGAZIG scale constitutes a validated and feasible tool for KOA assessment. ZAGAZIG scale correlated with WOMAC subscales (pain, stiffness and function), VAS and HAQ-II.

Contributors The first author propose ZAGAZIG scale. All three authors contribute equally in study design, clinical work, interpretation of the results and writing the manuscript. MAM acts as a gaurantor.

Funding The authors have not declared a specific grant for this research from any funding agency in the public, commercial or not-for-profit sectors.

Disclaimer The funders did not have any input in the development of the protocol and neither will they have input in the analysis of the data.

Competing interests None declared.

Patient and public involvement Patients and/or the public were not involved in the design, or conduct, or reporting, or dissemination plans of this research.

Patient consent for publication Not applicable.

Ethics approval This study was approved by the institutional review board (IRB) of Zagazig university number #5612 and all participants signed informed consent. The research was conducted by the principles of the Declaration of Helsinki.

Provenance and peer review Not commissioned; externally peer reviewed.

Data availability statement All data relevant to the study are included in the article or uploaded as supplementary information. No additional data available.

Open access This is an open access article distributed in accordance with the Creative Commons Attribution Non Commercial (CC BY-NC 4.0) license, which permits others to distribute, remix, adapt, build upon this work non-commercially, and license their derivative works on different terms, provided the original work is properly cited, appropriate credit is given, any changes made indicated, and the use is non-commercial. See: <http://creativecommons.org/licenses/by-nc/4.0/>.

ORCID iD

Mohamed Mortada <http://orcid.org/0000-0002-7198-9878>

REFERENCES

- Zhang Y, Jordan JM. Epidemiology of osteoarthritis. *Clin Geriatr Med* 2010;26:355–69.
- Bijlsma JWJ, Berenbaum F, Lafeber FPJG. Osteoarthritis: an update with relevance for clinical practice. *Lancet* 2011;377:2115–26.
- Funck-Brentano T, Cohen-Solal M. Subchondral bone and osteoarthritis. *Curr Opin Rheumatol* 2015;27:420–6.
- Zhu Z, Otahal P, Wang B, et al. Cross-Sectional and longitudinal associations between serum inflammatory cytokines and knee bone marrow lesions in patients with knee osteoarthritis. *Osteoarthritis Cartilage* 2017;25:499–505.
- Reynard LN, Barter MJ. Osteoarthritis year in review 2019: genetics, genomics and epigenetics. *Osteoarthritis Cartilage* 2020;28:275–84.
- Iagnocco A, Meenagh G, Riente L, et al. Ultrasound imaging for the rheumatologist XXIX. sonographic assessment of the knee in patients with osteoarthritis. *Clin Exp Rheumatol* 2010;28:643–6.
- Dieppe P. Osteoarthritis and related disorders. Introduction and history. In: Klippel JH, Dieppe PA, eds. *Rheumatology*. London: Mosby, 1998.
- Iagnocco A. Imaging the joint in osteoarthritis: a place for ultrasound? *Best Pract Res Clin Rheumatol* 2010;24:27–38.
- Iagnocco A, Perricone C, Scirocco C, et al. The interobserver reliability of ultrasound in knee osteoarthritis. *Rheumatology* 2012;51:2013–9.
- Möller I, Bong D, Naredo E, et al. Ultrasound in the study and monitoring of osteoarthritis. *Osteoarthritis Cartilage* 2008;16 Suppl 3:S4–7.
- Riecke BF, Christensen R, Torp-Pedersen S, et al. An ultrasound score for knee osteoarthritis: a cross-sectional validation study. *Osteoarthritis Cartilage* 2014;22:1675–91.
- Jordan KM, Arden NK, Doherty M, et al. EULAR recommendations 2003: an evidence based approach to the management of knee osteoarthritis: report of a task force of the standing Committee for international clinical studies including therapeutic trials (ESCSIT). *Ann Rheum Dis* 2003;62:1145–55.
- Tarhan S, Unlu Z, Goktan C. Magnetic resonance imaging and ultrasonographic evaluation of the patients with knee osteoarthritis: a comparative study. *Clin Rheumatol* 2003;22:181–8.
- Kellgren JH, Lawrence JS. Radiological assessment of osteoarthritis. *Ann Rheum Dis* 1957;16:494–502.
- Guermazi A, Hayashi D, Eckstein F, et al. Imaging of osteoarthritis. *Rheum Dis Clin North Am* 2013;39:67–105.
- Abraham AM, Goff I, Pearce MS, et al. Reliability and validity of ultrasound imaging of features of knee osteoarthritis in the community. *BMC Musculoskelet Disord* 2011;12:1.
- Roemer FW, Eckstein F, Hayashi D, et al. The role of imaging in osteoarthritis. *Best Pract Res Clin Rheumatol* 2014;28:31–60.
- Hall M, Doherty S, Courtney P, et al. Synovial pathology detected on ultrasound correlates with the severity of radiographic knee osteoarthritis more than with symptoms. *Osteoarthritis Cartilage* 2014;22:1627–33.
- Iagnocco A, Rizzo C, Gattamelata A, et al. Osteoarthritis of the foot: a review of the current state of knowledge. *Med Ultrason* 2013;15:35–40.
- Razek AAKA, Al Mahdy Al Belasy F, Ahmed WMS, et al. Assessment of articular disc displacement of temporomandibular joint with ultrasound. *J Ultrasound* 2015;18:159–63.
- Han D-S, Wu W-T, Hsu P-C, et al. Sarcopenia is associated with increased risks of rotator cuff tendon diseases among community-dwelling elders: a cross-sectional quantitative ultrasound study. *Front Med* 2021;8:630009.
- Razek AAKA, Fouda NS, Elmetwaley N, et al. Sonography of the knee joint(). *J Ultrasound* 2009;12:53–60.
- Grassi W, Filippucci E, Farina A. Ultrasonography in osteoarthritis. *Semin Arthritis Rheum* 2005;34:19–23.
- Iagnocco A. Ultrasound in osteoarthritis. *Clin Exp Rheumatol* 2014;32:S48–52.
- Eşen S, Akarırmak U, Aydın FY, et al. Clinical evaluation during the acute exacerbation of knee osteoarthritis: the impact of diagnostic ultrasonography. *Rheumatol Int* 2013;33:711–7.
- de Miguel Mendieta E, Cobo Ibáñez T, Usón Jaeger J, et al. Clinical and ultrasonographic findings related to knee pain in osteoarthritis. *Osteoarthritis Cartilage* 2006;14:540–4.
- Mermerci BB, Garip Y, Uysal RS, et al. Clinic and ultrasound findings related to pain in patients with knee osteoarthritis. *Clin Rheumatol* 2011;30:1055–62.
- Naredo E, Cabero F, Palop MJ, et al. Ultrasonographic findings in knee osteoarthritis: a comparative study with clinical and radiographic assessment. *Osteoarthritis Cartilage* 2005;13:568–74.
- Razek AAKA, El-Basyouni SR. Ultrasound of knee osteoarthritis: interobserver agreement and correlation with Western Ontario and McMaster universities osteoarthritis. *Clin Rheumatol* 2016;35:997–1001.
- Serban O, Porojan M, Deac M, et al. Pain in bilateral knee osteoarthritis - correlations between clinical examination, radiological, and ultrasonographical findings. *Med Ultrason* 2016;18:318–25.
- Beyers K, Bijlsma JW, Vriezekolk JE, et al. Ultrasonographic features in symptomatic osteoarthritis of the knee and relation with pain. *Rheumatology* 2014;53:1625–9.
- Bernardo-Bueno MM, Gonzalez-Suarez CB, Malvar AK, et al. Stratifying minimal versus severe pain in knee osteoarthritis using a musculoskeletal ultrasound protocol. *J Ultrasound Med* 2019;38:1–13.
- Altman R, Asch E, Bloch D. The American College of rheumatology criteria for the classification and reporting of osteoarthritis of the knee. *Arthritis Rheum* 1986;29:1039–49.
- Bellamy N, Buchanan WW, Goldsmith CH, et al. Validation study of WOMAC: a health status instrument for measuring clinically important patient relevant outcomes to antirheumatic drug therapy in patients with osteoarthritis of the hip or knee. *J Rheumatol* 1988;15:1833–40.
- Cheng S-F, Hester NO, Foster RL, et al. Assessment of the convergent validity of pain intensity in the pain sensory tool. *J Nurs Res* 2003;11:93–100.
- Maska L, Anderson J, Michaud K. Measures of functional status and quality of life in rheumatoid arthritis: health assessment questionnaire disability index (HAQ), modified health assessment questionnaire (MHAQ), multidimensional health assessment questionnaire (MDHAQ), health assessment questionnaire II (HAQ-II), improved health assessment questionnaire (improved HAQ), and rheumatoid arthritis quality of life (RAQoL). *Arthritis Care Res* 2011;63:S4–13.
- Backhaus M, Burmester GR, Gerber T, et al. Guidelines for musculoskeletal ultrasound in rheumatology. *Ann Rheum Dis* 2001;60:641–9.
- Mortada M, Zeid A, Al-Toukhy MAE-H, et al. Reliability of a proposed ultrasonographic grading scale for severity of primary knee osteoarthritis. *Clin Med Insights Arthritis Musculoskelet Disord* 2016;9:CMAMD.S38141–6.
- Hartung W, Kellner H, Strunk J, et al. Development and evaluation of a novel ultrasound score for large joints in rheumatoid arthritis: one year of experience in daily clinical practice. *Arthritis Care Res* 2012;64:675–82.