


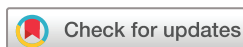BMJ Open Two-step versus 1-step subretinal injection to compare subretinal drug delivery: a randomised study protocol

Matthew P Simunovic ^{1,2}, Emily H Shao,² Perach Osaadon,² Muhammad Bayu Sasongko,² Lay Khoon Too¹

To cite: Simunovic MP, Shao EH, Osaadon P, *et al.* Two-step versus 1-step subretinal injection to compare subretinal drug delivery: a randomised study protocol. *BMJ Open* 2021;**11**:e049976. doi:10.1136/bmjopen-2021-049976

► Prepublication history and additional supplemental material for this paper are available online. To view these files, please visit the journal online (<http://dx.doi.org/10.1136/bmjopen-2021-049976>).

Received 06 February 2021
Accepted 08 November 2021



© Author(s) or their employer(s) 2021. Re-use permitted under CC BY-NC. No commercial re-use. See rights and permissions. Published by BMJ.

¹Save Sight Institute, University of Sydney, Sydney, New South Wales, Australia

²Retinal Unit, Sydney Eye Hospital, Sydney, New South Wales, Australia

Correspondence to

Matthew P Simunovic;
matthew.simunovic@sydney.edu.au

ABSTRACT

Introduction There is increasing interest in subretinal injections as a surgical procedure, largely as a result of emerging treatments for ocular diseases which necessitate this manoeuvre. However, surgical variables in the efficacy of such treatments have to date been largely overlooked and the proportion of drug which reaches the intended compartment of the subretinal space remains unknown. Our aims are twofold: first, to determine the proportion of subretinally injected medication retained following surgical delivery and second, to compare two different techniques of injection ('1-step' vs '2-step').

Methods We outline a randomised controlled trial of subretinal injection of alteplase following vitrectomy for the management of submacular haemorrhage secondary to age-related macular degeneration. Patients will be randomised to receive either 1-step injection, where the therapeutic solution simultaneously defines the surgical plane or 2-step injection, where the surgical plane is first identified with balanced salt solution prior to injection of subretinal alteplase, as outlined below. Sodium fluorescein will be used as an optical label to track drug reflux into the vitreous cavity using quantitative protocols established in our laboratory. All patients will undergo fluid air exchange at the completion of surgery, with injection of bevacizumab 1.25 mg and 20% sulfahexafluoride gas as the vitreous substitute (both of which may help improve outcomes). Alteplase, sodium fluorescein and bevacizumab will all be used for off-label indications in the trial.

Ethics and dissemination Ethical approval has been obtained from the South Eastern Sydney Local Health District's Human Research Ethics Committee (HREC 17/092). The results of this trial will be disseminated in peer-reviewed proceedings (associated with conference presentation) and in scholarly journals.

Trial registration number ACTRN12619001121156.

INTRODUCTION

Subretinal injection is an invasive method of delivering therapeutic substances to the outer retina.^{1 2} It bypasses intraocular distribution and the barrier of the internal limiting membrane, a basement membrane of the retina which acts as a barrier for drugs (such as tissue plasminogen activator) and other agents (such as adenoviral vectors).^{3 4} Until recently, this mode of delivery was used

Strengths and limitations of this study

- This is a first-in-human trial investigating the fate of subretinally injected medication.
- We will use a fluorophotometric protocol developed in our laboratory to quantify reflux/wastage of subretinally delivered alteplase for the treatment of submacular haemorrhage.
- This study will also compare two alternative surgical approaches to subretinal drug delivery.
- The results of this study may be applied with caution to other disease models; however, proportional reflux may be greater in conditions in which there is no pre-existing subretinal fluid.

almost exclusively to deliver tissue plasminogen activator (tPA) and its derivatives as part of the management of submacular haemorrhage.⁵ However, there is increasing interest in subretinal drug delivery due to emerging treatments of retinal disease, such as retinal gene and stem cell therapies, which may mandate this route.^{2 6-8}

Substantial investment has been made in the research and development of gene therapies and one, vortigene neparvovec-rzyl (Luxturna)^{6 7} for the treatment of Leber's Congenital Amaurosis 2 (LCA2), has achieved regulatory approval in North America, Europe, the UK and Australia. However, surgery is one of the critical variables which is overlooked when considering the efficacy of these treatments.^{1 2} Indeed, we know little about how much drug is actually delivered to the intended surgical space and until recently, the only quantitative measurements undertaken were on cadaveric animal models and using advanced optical coherence tomographs to estimate the retained subretinal bleb volume.⁹ Even when no reflux of triamcinolone is observed, losses were estimated to be at least 12%.⁹ Furthermore, there is conjecture regarding the optimum method of performing subretinal injections.

Although early studies employed manual injection techniques,^{6 7} this approach has the disadvantage of generally requiring an assistant surgeon to depress the syringe plunger (which is connected to the subretinal cannula via flexible tubing). This effectively dissociates the process, with the attendant difficulties introduced through delays associated with the surgeon identifying the likely appropriate depth and the commencement of injection by the assistant. Furthermore, manual injection cannot adequately control injection pressure: this is important because inappropriate flow rates/injection pressures may result in atrophic changes in the retinal pigment epithelium (RPE).¹⁰ For this reason, many surgeons have opted for injection techniques in which the syringe is controlled via a foot-pedal.¹¹ This enables precise control or timing by the surgeon; furthermore, safety measures such as limiting the flow of fluid/pressure during injection may be incorporated into the instrument settings. This has been demonstrated to negate or minimise the possibility of the atrophic changes which may be seen with manual injection.¹² However, there remain two competing methods of subretinal injection. In the first method—hereafter referred to as 1-step injection—the therapeutic solution simultaneously delivers treatment and defines the surgical plane. This method was employed in the early gene therapy trials which ultimately led to the development of voretigene neparvovec-rzyl.⁷ In the second method—hereafter referred to as 2-step injection^{2 11}—the surgical plane is first defined by the subretinal injection of a small quantity of balanced salt solution (eg, around 0.2–0.3 mL). Subsequently, the therapeutic solution is delivered into the subretinal space via the same retinotomy site.

AIMS

The aims of our study are twofold. First, we aim to employ a quantitative method developed in our laboratory which uses sodium fluorescein as an optical label to measure the reflux of subretinally delivered drugs which we have described in detail previously.¹ Second, we aim to compare 1-step and 2-step injection techniques in terms of percentage of therapeutic solution ‘wasted’ (as measured in the first aim) during the surgical procedure to deliver therapeutic solutions into the subretinal space.

METHODS

Study design

This is a single-centre randomised controlled trial which will be conducted in a large tertiary-referral teaching hospital. The proposal follows the guidelines employed in the Standard Protocol Items: Recommendations for Interventional Trials checklist.¹³ We will recruit patient presenting with vision loss from subretinal haemorrhage secondary to neovascular age-related macular degeneration. Though a relatively rare phenomenon, the documented natural history of this complication is typically

poor and there is some limited evidence to suggest that displacement of haemorrhage away from the central macula is advantageous (as opposed to surgical evacuation, which does not significantly improve clinical outcomes).⁵

Patients presenting with vision loss ($\leq 6/60$) of 7 or fewer days due to submacular haemorrhage secondary to neovascular age-related macular degeneration involving the fovea and over greater than 1 disc area (estimated on clinical examination) will be recruited into this study after obtaining written informed consent. Exclusion criteria include symptoms of duration > 7 days, the presence of a significant concomitant ocular condition limiting vision in the study eye, vision of less than hand movements, those unable to adhere to postoperative positioning and patients with known allergy to the study medications.

Clinical examination will consist of best-corrected visual acuity testing, followed by clinical examination including estimation of intraocular pressure and anterior segment examination with a slit-lamp biomicroscope. The ocular fundus will be assessed with a fundus lens at the slit-lamp biomicroscope and with a binocular indirect ophthalmoscope. Spectral-domain optical coherence tomography will be performed with a Zeiss Cirrus HD-OCT 5000 (Carl Zeiss AG, Oberkochen, Germany; macular cube 512×128 scan) to differentiate subsensory retinal from sub-RPE haemorrhage. Additionally, OCTs will be scrutinised for other pertinent features, including (but not limited to) the presence of sub-RPE, subsensory retinal or intraretinal fluid, presence of an RPE rip, macular holes, etc. Where required—for example, in cases of dense and/or thick haemorrhage obscuring the RPE—short-wavelength fundus autofluorescence with an Optos 200 Tx (Optos, Dumfermline, Scotland) will be employed to confirm subretinal (blocked autofluorescence), as opposed to sub-RPE haemorrhage (preserved autofluorescence).

Patients will be randomly allocated via binary random number generation into groups to undergo either 1-step or 2-step subretinal injection following pars plana vitrectomy (combined phacovitrectomy not permitted). Patients and staff completing outcome assessments will be masked regarding group allocation (allocation will be performed by MPS as above). All patients will undergo a standard valved three-port 25 gauge trans-pars plana vitrectomy with an Alcon Constellation device (Alcon, Fort Worth, TX, USA), with visualisation provided by the Zeiss Resight 500 system (128D and 60D lenses). Following completion of core and peripheral vitrectomy (with induction of posterior vitreous detachment, where required), a 38 g Teflon tipped subretinal cannula mounted onto a specially designed 1 mL syringe (MedOne, Sarasota, FL, USA) will be used to inject into the subretinal space outside of the region of pre-existing detachment from submacular haemorrhage. All injections will be performed under the control of the operating surgeon using a foot-actuated plunger connected to the ‘viscous fluid control’ line of the Constellation system using previously described methods to minimise

the occurrence of air-bubbles.¹¹ Patients undergoing the 1-step procedure will have 0.1 mL of the therapeutic solution (containing 50 µg of Alteplase and 10 µg of sodium fluorescein) injected subretinally following completion of vitrectomy. Patients undergoing the 2-step procedure will have 0.2 mL of balanced salt solution first injected to define the surgical plane. Following this, 0.1 mL of the therapeutic solution (containing 50 µg of Alteplase and 10 µg of sodium fluorescein; these doses have been demonstrated to be non-toxic)^{14–16} will be injected through the same retinotomy using a new subretinal cannula and syringe. After completion of the subretinal injection, the peripheral retina is carefully inspected by external scleral depression with a cryotherapy probe: any holes or tears are treated prophylactically. An air-for-fluid exchange will be performed at case completion and the aspirated fluid from the intraocular cavity sent for analysis, including measurement of its total volume and fluorescein concentration following centrifuging using a protocol developed in our laboratory and which has been previously described. Sulphur hexafluoride gas (concentration 20%) will be used as the vitreous substitute and 1.25 mg of bevacizumab injected into the vitreous cavity (see online supplemental video).¹⁷ Initially, patients will be positioned face up until they are in recovery (about 30 min) and then positioned upright or operated side down as appropriate to encourage the migration of blood from the central to the peripheral retina.

Patients will undergo assessment on day 1, week 1, month 1 and month 3 following treatment. Examinations will consist of evaluation of visual acuity, intraocular pressure as well as anterior and posterior segment examination. At 1 and 3 months, optical coherence tomography will be repeated and analysed as outlined above. In the case of missing data for these secondary outcome measures, Bootstrapping methods will be used to impute missing values (the primary outcome measure will be determined at the time of surgery: we do not anticipate dropouts at this timepoint). Patients will be reviewed thereafter according to standard of care, as deemed appropriate by their treating ophthalmologist.

Outcomes

The aim of this study is to determine the optimal approach to achieving target drug doses in the subretinal space. Accordingly, the primary outcome measure will be the proportion of drug refluxed by completion of the surgical procedure.

Secondary outcomes include the duration of surgery and neural retinal thickness^{18 19} estimated by Zeiss Cirrus HD-OCT 5000 OCT at the fovea (ETDRS area 1, ie, central 1 mm diameter via the macular cube 512×128 scan, with segmentation confirmed and optimised, where required, by a retinal specialist) at 3 months versus baseline, visual acuity at 3 months and change in visual acuity from baseline to 3 months. Exploratory structural outcomes will include ellipsoid zone status (normal/thinned/disrupted/obliterated), presence of RPE rips

and detachments, efficacy of displacement of blood from the foveal centre at day 1 (estimated clinically: none/partial/complete). Adverse events will be recorded, whether these are deemed to be related to the investigative procedure or not.

Data and procedural adherence will be reviewed at the halfway point of the trial by the data monitoring committee, which will be composed of three ophthalmologists and a study co-ordinator (orthoptist). Interim statistical review will be conducted according to the trial protocol; if one method is demonstrated to be statistically superior to another in terms of the primary outcome, the trial will be terminated early.

Sample size

We assume that the average reflux in the 1-step injection will mirror results from injections of triamcinolone in animal models (average 60.5% reflux).⁹ Furthermore, we hypothesise that 2-step injection reflux should mirror that of the best-performing injections where no triamcinolone was observed to be refluxed (12%; as the surgical plane will already be defined and that the higher flows necessary to initiate a subretinal bleb are not necessary). Therefore, for an α of 0.05 and a power of 0.8, we estimate that a total sample size of 12 would be required.

Personnel

The research team will consist at any one time of three vitreoretinal surgeons who are responsible for clinical care and performing the study procedure. One postdoctoral research assistant will conduct fluorophotometric and volumetric measurements on the obtained ocular fluid sample. A research orthoptist will perform parts of the clinical assessment and will be responsible for coordinating study visits.

Analysis

Intraocular fluid will undergo fluorophotometric analysis using a previously published protocol validated in our laboratory, which negates the effects of possible extinction of fluorescence from contamination with blood.¹ Repeat calibration and cross-referencing with undiluted therapeutic solution will be performed for each sample to avoid variation introduced through variations in the concentration of fluorescein (introduced in the manufacture of fluorescein or the dilution procedure). Duration of surgery will be evaluated from surgical videos and/or case documentation in the patient's surgical file. Imaging and visual acuity data outcomes will be obtained from the patients' medical/electronic medical records. Comparisons of means will be performed with unpaired t-tests (previous estimates⁹ of the distribution of subretinal injection wastage suggest normality; D'Agostino-Pearson Test $A2=0.48$; $p=0.18$) in GraphPad Prism V.8. Data will be stored in duplicate in anonymised form: the study team will maintain sole access to data.

Ethics

The project has been approved by the South East Sydney Human Research Ethics Committee (HREC 17/092; protocol version 2) and has been registered with the Australian and New Zealand Clinical Trials Registry (ACTRN12619001121156). Protocol amendments will be approved by the HREC and the relevant details updated on the Australian and New Zealand Clinical Trials Registry, where appropriate.

Dissemination

The method of estimating subretinal drug loss has been published already in a leading ophthalmic journal.¹ Results of the trial will be disseminated by the authors of this manuscript at scholarly meetings and in ophthalmic journals, with access to full data sets.

Patient and public involvement

Although patients were not directly involved in the conception or design of this study, the South East Sydney Human Research Ethics Committee, which approved the study, has lay members who helped assess, and approve, this trial protocol.

DISCUSSION

Subretinal injection of therapeutic solutions has largely been limited to the delivery of tPA and its derivatives as an off-label indication for the dissolution and displacement of submacular haemorrhage.⁵ However, newer retinal therapies, such as gene therapies (including voretigene neparvovec-rzyl, or Luxturna, for LCA2) mandate subretinal injection of small volumes of therapeutic solutions (0.3 mL in the case of voretigene neparvovec-rzyl;⁷ 0.1 mL in the case of other gene therapies in clinical trials)^{8 20} and have extended the indications for this approach. However, we have little understanding of what proportion of drug intended for the subretinal space actually reaches the desired location. Sodium fluorescein has only recently been described as an optical label to quantify drug retention following surgery, though older reports have used sodium fluorescein to assess subretinal injection qualitatively.²¹ Our fluorophotometric method will be applied to study subretinal injection in the context of submacular haemorrhage due to neovascular age-related macular degeneration to determine the proportion of drug refluxed during surgery. Furthermore, we aim to compare two different surgical approaches: 2-step and 1-step injection. It will be noted that caution needs to be exercised in extending the results of the planned trial to model subretinal delivery of gene therapy: in particular, patients with submacular haemorrhage already have the correct surgical plane defined in the central macula. Therefore, we may merely be identifying the difference between techniques in the first stage of injections, that is, where the surgical space must be accessed and the plane defined, rather than the later stages, where the subretinal bleb is extended. However, this is likely to represent the

major difference between the two techniques. Further consideration should also be given to its general applicability, especially in the context of patients with inherited retinal degeneration.²⁰ The latter is commonly associated with extensive retinal remodelling and thinning (with some exceptions): this may result in difficulties in successfully identifying the correct surgical space to commence injection, and it could be argued that in such patients, the two-step approach is preferred for this reason alone.

Contributors MPS: study conception and design, principle surgeon, drafting manuscript. EHS, PO and MBS: subject recruitment, assisting surgeon, review of manuscript. LKT: development and implementation of fluorophotometric protocol, review of manuscript.

Funding MPS is supported by a Career Development Award from the Foundation Fighting Blindness, USA CD-CL-0816-0710-SYD.

Competing interests None declared.

Patient and public involvement Patients and/or the public were not involved in the design, or conduct, or reporting or dissemination plans of this research.

Patient consent for publication Not required.

Provenance and peer review Not commissioned; externally peer reviewed.

Supplemental material This content has been supplied by the author(s). It has not been vetted by BMJ Publishing Group Limited (BMJ) and may not have been peer-reviewed. Any opinions or recommendations discussed are solely those of the author(s) and are not endorsed by BMJ. BMJ disclaims all liability and responsibility arising from any reliance placed on the content. Where the content includes any translated material, BMJ does not warrant the accuracy and reliability of the translations (including but not limited to local regulations, clinical guidelines, terminology, drug names and drug dosages), and is not responsible for any error and/or omissions arising from translation and adaptation or otherwise.

Open access This is an open access article distributed in accordance with the Creative Commons Attribution Non Commercial (CC BY-NC 4.0) license, which permits others to distribute, remix, adapt, build upon this work non-commercially, and license their derivative works on different terms, provided the original work is properly cited, appropriate credit is given, any changes made indicated, and the use is non-commercial. See: <http://creativecommons.org/licenses/by-nc/4.0/>.

ORCID iD

Matthew P Simunovic <http://orcid.org/0000-0003-0596-1356>

REFERENCES

- 1 Simunovic MP, Osaadon P, Too LK. Sodium fluorescein as an optical label to evaluate subretinal injection. *Retina*. In Press 2020. doi:10.1097/IAE.0000000000002800. [Epub ahead of print: 07 Apr 2020].
- 2 Simunovic MP, Xue K, Jolly JK, et al. Structural and functional recovery following limited iatrogenic macular detachment for retinal gene therapy. *JAMA Ophthalmol* 2017;135:234–41.
- 3 Kwan ASL, Vijayasekaran S, McAllister IL, et al. A study of retinal penetration of intravitreal tenecteplase in pigs. *Invest Ophthalmol Vis Sci* 2006;47:2662–7.
- 4 McGregor JE, Godat T, Dhakal KR, et al. Optogenetic restoration of retinal ganglion cell activity in the living primate. *Nat Commun* 2020;11:1703.
- 5 Stanescu-Segall D, Balta F, Jackson TL. Submacular hemorrhage in neovascular age-related macular degeneration: a synthesis of the literature. *Surv Ophthalmol* 2016;61:18–32.
- 6 Chao DL, Burr A, Pennesi M. RPE65-related leber congenital amaurosis / early-onset severe retinal dystrophy. In: Adam MP, Ardinger HH, Pagon RA, et al, eds. *GeneReviews*(®). Seattle (WA), 2019.
- 7 Russell S, Bennett J, Wellman JA, et al. Efficacy and safety of voretigene neparvovec (AAV2-hRPE65v2) in patients with RPE65-mediated inherited retinal dystrophy: a randomised, controlled, open-label, phase 3 trial. *Lancet* 2017;390:849–60.
- 8 Edwards TL, Jolly JK, Groppe M, et al. Visual acuity after retinal gene therapy for choroideremia. *N Engl J Med* 2016;374:1996–8.

- 9 Hsu ST, Gabr H, Viehland C, *et al.* Volumetric measurement of subretinal blebs using microscope-Integrated optical coherence tomography. *Transl Vis Sci Technol* 2018;7:19.
- 10 Scruggs BA, Jiao C, Cranston CM, *et al.* Optimizing donor cellular dissociation and subretinal injection parameters for stem cell-based treatments. *Stem Cells Transl Med* 2019;8:797–809.
- 11 Xue K, Groppe M, Salvetti AP, *et al.* Technique of retinal gene therapy: delivery of viral vector into the subretinal space. *Eye* 2017;31:1308–16.
- 12 Takahashi K, Morizane Y, Hisatomi T, *et al.* The influence of subretinal injection pressure on the microstructure of the monkey retina. *PLoS One* 2018;13:e0209996.
- 13 Chan A-W, Tetzlaff JM, Altman DG, *et al.* SPIRIT 2013 statement: defining standard protocol items for clinical trials. *Ann Intern Med* 2013;158:200–7.
- 14 Salvetti AP, Patricio MI, Barnard AR, *et al.* Impact of vital dyes on cell viability and transduction efficiency of AAV vectors used in retinal gene therapy surgery: an in vitro and in vivo analysis. *Transl Vis Sci Technol* 2017;6:4.
- 15 Kato S, Madachi-Yamamoto S, Hayashi Y, *et al.* Effect of sodium fluorescein on neurite outgrowth from the retinal explant culture: an in vitro model for retinal toxicity. *Brain Res* 1983;313:143–7.
- 16 Lewis H, Resnick SC, Flannery JG, *et al.* Tissue plasminogen activator treatment of experimental subretinal hemorrhage. *Am J Ophthalmol* 1991;111:197–204.
- 17 Novelli FJD, Preti RC, Monteiro MLR, *et al.* A new method of subretinal injection of tissue plasminogen activator and air in patients with submacular hemorrhage. *Retina* 2017;37:1607–11.
- 18 Chalam KV, Bressler SB, Edwards AR, *et al.* Retinal thickness in people with diabetes and minimal or no diabetic retinopathy: Heidelberg spectralis optical coherence tomography. *Invest Ophthalmol Vis Sci* 2012;53:8154–61.
- 19 Bressler NM, Edwards AR, Antoszyk AN, *et al.* Retinal thickness on stratus optical coherence tomography in people with diabetes and minimal or no diabetic retinopathy. *Am J Ophthalmol* 2008;145:894–901.
- 20 Davis JL, Gregori NZ, MacLaren RE, *et al.* Surgical technique for subretinal gene therapy in humans with inherited retinal degeneration. *Retina* 2019;39 Suppl 1:S2–8.
- 21 Khan MA, Shahlaee A, Bansal AS, *et al.* Fluorescein-assisted subretinal tissue plasminogen activator (tPA) delivery for submacular hemorrhage. *Retina* 2017;37:1203–6.