

Appendices of Comparing Lung Ultrasound: Extensive vs Short in COVID-19 (CLUES).**Supplementary table 1: Sonographic features of COVID-19 pneumonia compared to CT findings, after Peng et al. [18]**

Lung ultrasound	Chest CT
Thickened & irregular pleural line	Thickened pleura
B-lines (discrete, multifocal or confluent)	Ground glass opacities (GGOs)
Confluent B-lines	Pulmonary infiltrating shadow
Sub-pleural consolidations or 'skip' lesions	Sub-pleural consolidation
Both non-translobar and translobar consolidation	Translobar consolidation
Rare pleural effusion	Rare pleural effusion
Multi-zone, patchy distribution of abnormalities	Multiple lobes affected
<p>Early stage and mild infection: focal B-lines are the main feature.</p> <p>Progressive stage and severe infection: alveolar interstitial syndrome is the main feature.</p> <p>Convalescence: returning of A-lines are the main feature.</p> <p>Pulmonary fibrosis: pleural line thickening with uneven B lines are the main feature.</p>	<p>Very early stage: negative or atypical findings in lung CT images.</p> <p>Pneumonia: diffuse scattered or ground glass opacities are seen.</p> <p>With progression of the disease further lung consolidation are the main feature.</p>

Supplementary table 2: McNemar test results.

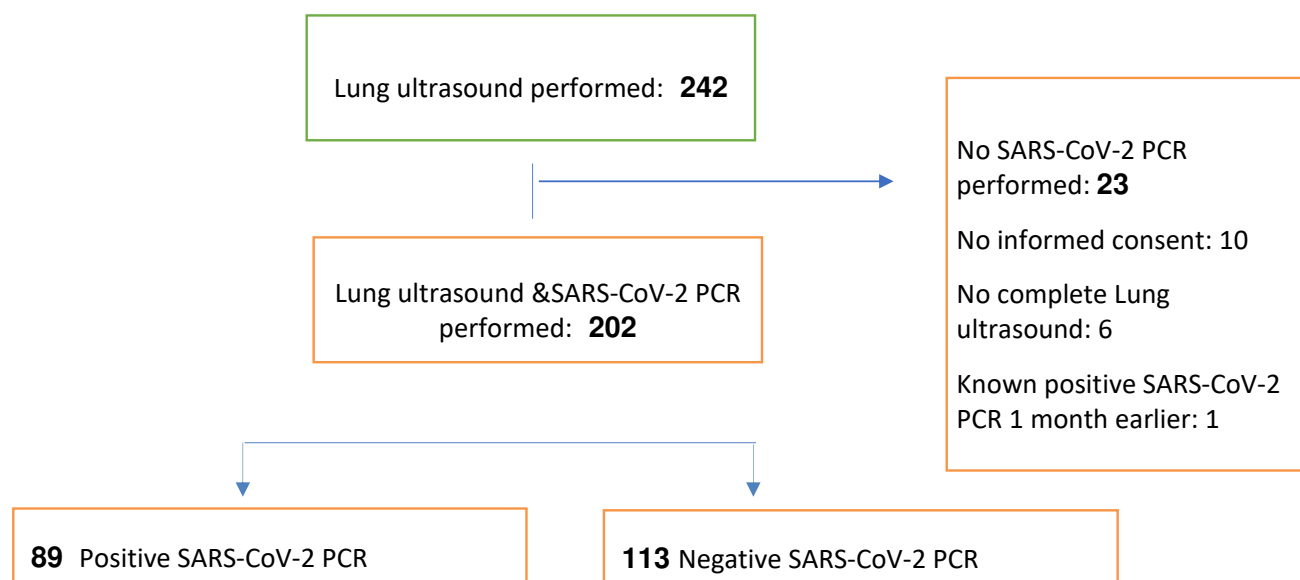
McNemar test	12-zone vs 8-points	12-zone vs 6-points	8-points vs 6-points
--------------	---------------------	---------------------	----------------------

SARS-CoV-2 PCR +	0.000	0.250	0.022
SARS-CoV-2 PCR -	0.238	0.000	0.004

McNemar test	12-zone vs 8 points	12-zone vs 6-points	8-points vs 6-points
Final diagnosis +	0.003	0.625	0.022
Final diagnosis -	0.332	0.000	0.004

Supplementary table 3: descriptive statistics of clinical symptoms.

Symptoms	SARS-CoV-2 PCR +	SARS-CoV-2 PCR -	P value
Fever	63 (70.0)	47 (41.6)	0.001
Coughing	71 (78.9)	64 (56.6)	0.000
Wheezing	2 (2.1)	0 (0.0)	0.001
Dyspnea	60 (66.7)	52 (46.0)	0.001
Fatigue	33 (34.4)	24 (21.2)	0.000
Headache	15 (16.7)	14 (12.4)	0.086
Diarrhea	17 (18.9)	7(6.2)	0.000
Muscle pain	21 (23.3)	10 (8.8)	0.000

Study population flowchart.**Entrustable Professional Activity (EPA).**

EPA is a key task of a discipline (e.g. acute internal medicine) that an individual can be trusted to perform in a given health care context, once sufficient competence has been demonstrated. (after ten Cate O. Entrustability of professional activities and competency-based training. *Med Educ.* 2005;39(12):1176-1177. doi:10.1111/j.1365-2929.2005.02341.x)

EPA Level	
1	Observation, no task performance.
2	Task performance whilst receiving active supervision.
3	Task performance with remote supervision.
4	Independent in task performance.
5	Independent and supervising others.

