

BMJ Open PCSK9 inhibition in patients with acute stroke and symptomatic intracranial atherosclerosis: protocol for a prospective, randomised, open-label, blinded end-point trial with vessel-wall MR imaging

Yen-Chu Huang ,^{1,2} Chia-Hao Chang,³ Yuan-Hsiung Tsai ,^{2,4}
Hsu-Huei Weng ,^{4,5} Leng-Chieh Lin,⁶ Jiann-Der Lee^{1,2}

To cite: Huang Y-C, Chang C-H, Tsai Y-H, *et al.* PCSK9 inhibition in patients with acute stroke and symptomatic intracranial atherosclerosis: protocol for a prospective, randomised, open-label, blinded end-point trial with vessel-wall MR imaging. *BMJ Open* 2022;**12**:e060068. doi:10.1136/bmjopen-2021-060068

► Prepublication history and additional supplemental material for this paper are available online. To view these files, please visit the journal online (<http://dx.doi.org/10.1136/bmjopen-2021-060068>).

Received 09 December 2021
Accepted 04 March 2022



© Author(s) (or their employer(s)) 2022. Re-use permitted under CC BY-NC. No commercial re-use. See rights and permissions. Published by BMJ.

For numbered affiliations see end of article.

Correspondence to

Dr Yen-Chu Huang;
ychu.huang@msa.hinet.net

ABSTRACT

Introduction Dual antiplatelet therapy and high-intensity statins are the mainstay treatment in patients with acute stage, symptomatic intracranial atherosclerotic stenosis (ICAS). Alirocumab is a monoclonal antibody that can inhibit proprotein convertase subtilisin–kexin type 9 and effectively lower low-density lipoprotein cholesterol levels with less side effects than statins. We hypothesise that alirocumab treatment in addition to statin therapy could stabilise intracranial plaque and reduce arterial stenosis.

Methods and analysis In this prospective, randomised, open-label, blinded end-point study, we will use high-resolution vessel-wall MRI to evaluate the efficacy and safety of alirocumab in patients who had an acute ischaemic stroke from ICAS. We will recruit 66 patients who had an acute ischaemic stroke within 7 days of symptom onset, who had symptomatic intracranial artery stenosis (>30%) at the middle cerebral artery, basilar artery or intracranial internal carotid artery. Among them, 22 patients will be randomised to the intervention group to receive treatment with 75 mg alirocumab subcutaneously every 2 weeks for a total of 26 weeks, while those in the control group will not. All patients in both groups will receive antiplatelet agents and high-intensity statins, including 20 mg rosuvastatin or 40–80 mg atorvastatin or at the maximum tolerated dose. All of them will undergo MRI at recruitment and after 26 weeks. The primary outcomes are changes in intracranial atherosclerotic plaques in the MRI before and after 6 months treatment. This trial is being conducted at Chang Gung Memorial Hospital at Chiayi, Taiwan.

Ethics and dissemination This trial has been approved by the Institutional Review Board of Chang Gung Memorial Hospital (approval no. 202 002 482A3). Written informed consent will be obtained from all research participants. Study results will be published as peer-reviewed articles.

Trial registration number ClinicalTrials.gov, Identifier: NCT05001984; Pre-results.

Strengths and limitations of this study

- This is the first trial to assess the efficacy of a pro-protein convertase subtilisin–kexin type 9 inhibitor for the regression of intracranial atherosclerotic plaque after acute stroke beyond current best medical treatment.
- Due to the small sample size, it may be difficult to reach statistical significance for the secondary end-points, such as major cardiovascular events or functional outcomes.
- This trial is designed as a prospective randomised open-label blinded end-point trial, because this design entails low costs and renders patient recruitment easier; however, it may have the inherent drawbacks of investigator bias.

INTRODUCTION

Intracranial atherosclerotic stenosis (ICAS) is one of most common causes of ischaemic stroke, and is particularly prevalent among Asians.¹ It is associated with the highest rate of recurrent stroke compared with other aetiologies.^{2,3} This higher rate of stroke recurrence is related to haemodynamic compromise, artery-to-artery emboli and impaired emboli clearance.⁴ In addition, plaques with large lipid cores, fibrous caps or intraplaque haemorrhage, are more vulnerable to rupture, resulting in embolic stroke in locations downstream.^{5,6} Moreover, ICAS has been reported to cause branch atheromatous disease when atherosclerotic plaques occlude the origin of large calibre penetrating arteries.⁷ Branch atheromatous disease is more likely to have progressive motor deficits and poor functional outcomes, compared with other subcortical infarction due to hypertensive



arteriopathy.⁸⁹ Therefore, there is an urgent need to evaluate the effective management of ICAS.

The treatment of ICAS nowadays primarily focuses on secondary prevention to reduce stroke recurrence, including antiplatelet therapy, lipid-lowering treatments, interventional therapy and risk factor modification.¹⁰ Recent trials showed that early and short-term dual antiplatelet therapy might reduce the probability of recurrent stroke in patients who had a minor stroke or high-risk transient ischaemic attack (TIA).^{11 12} A retrospective study reported that dual antiplatelet therapy was beneficial for reducing the events of myocardial infarction, recurrent stroke and all-cause death in large atherosclerotic stroke.¹³ Dual antiplatelet therapy in patients with symptomatic ICAS for 90 days was used in the Stenting and Aggressive Medical Therapy for Preventing Recurrent Stroke in Intracranial Stenosis (SAMMPRIS) trial,¹⁴ which demonstrated a lower rate of recurrent stroke in patients with ICAS with 70%–99% stenosis compared with historical controls.¹⁵

The Stroke Prevention by Aggressive Reduction in Cholesterol Levels trial was the first one to show the effectiveness of high-intensity statins, atorvastatin 80 mg daily, for reducing the risk of recurrent stroke (HR 0.84 (95% CI 0.71 to 0.99)) in comparison to a placebo.¹⁶ High-intensity statins were used in the SAMMPRIS trial and became the standard treatment for patients with ICAS. Nowadays, the guidelines recommend to start or continue statin treatment as early as possible in acute ischaemic stroke.¹⁷ Some guidelines also suggest moderate-intensity or high-intensity statin therapy for patients with TIA or ischaemic stroke of atherosclerotic pathology, independent of the baseline low-density lipoprotein cholesterol (LDL-C).¹⁸ Fixed-dose combinations of statin and ezetimibe are also the first approach for patients with atherosclerotic cardiovascular disease and high LDL-C levels.¹⁹

However, high-intensity statin treatment is related to higher side effects, such as myalgia and abnormal liver function, which lead to suboptimal treatment. Monoclonal antibodies that inhibit proprotein convertase subtilisin–kexin type 9 (PCSK9) have emerged as a new class of drugs that effectively lower LDL cholesterol levels by approximately 60%.^{20 21} Recent evidence has shown that the use of PCSK9 inhibitors in patients with hyperlipidaemia or atherosclerotic cardiovascular disease significantly reduced the risk of major adverse cardiovascular events, including stroke risk (relative risk, 0.78 (95% CI 0.67 to 0.89); $p=0.0005$).²² High-intensity statin treatment also significantly reduced intracranial atherosclerotic plaques after acute stroke by ICAS as documented by high-resolution MRI.²³ Therefore, studies are needed to investigate the utility of PCSK9 inhibition in patients with symptomatic ICAS with the aim of reducing stroke risk.

In this trial, we will conduct a prospective, randomised, open-label, blinded end-point study using high-resolution MRI in patients who had an acute ischaemic stroke from ICAS, to evaluate the efficacy and safety of alirocumab, a monoclonal antibody against PCSK9. We hypothesise that

alirocumab treatment in addition to statin therapy could stabilise intracranial plaques and reduce arterial stenosis.

METHODS AND ANALYSIS

Study design

In this prospective, randomised, open-label, blinded end-point study, we will recruit 66 patients with acute infarction within 7 days of stroke onset, who had >30% intracranial artery stenosis, including the intracranial internal carotid artery, the M1 or M2 of the middle cerebral artery (MCA), or the basilar artery. We exclude patients with extracranial artery stenosis >50% (carotid or proximal vertebral arteries), cardioembolic stroke (valvular heart disease, atrial fibrillation or aortic arch atheroma) and severe renal or hepatic abnormalities.

After reviewing the eligibility criteria, 22 patients will be randomised to the intervention group to receive treatment with 75 mg alirocumab subcutaneously every 2 weeks for a total of 26 weeks (figure 1). Additionally, patients in the intervention group will also be treated with high-intensity statins, including atorvastatin 40–80 mg or rosuvastatin 20 mg (or at the maximum tolerated dose). The other 44 patients will be randomised to the control group and will receive treatment with high-intensity statins (or at the maximum tolerated dose). The study is being conducted from August 2021 to July 2024 at Chang Gung Memorial Hospital at Chiayi, Taiwan.

The trial protocol has been approved by the institutional review board at Chang Gung Memorial Hospital. All patients will be required to sign their written informed consent before recruitment into the study.

Study population

Patients will be included if they: (1) are diagnosed with ischaemic stroke with visible acute infarction in the territory of symptomatic ICAS on diffuse-weighted imaging (DWI), (2) have a total score of 1–15 in National Institutes of Health Stroke Scale (NIHSS), (3) have symptomatic stenosis (>30%) of the intracranial artery, including the intracranial internal carotid artery, the M1 or M2 of the MCA, or basilar artery, (4) could receive alirocumab and statin treatment within 7 days of stroke onset. We will exclude patients with other determined causes of stroke, such as arterial dissection or vasculitis, and also exclude those at high risk of having a cardioembolic source, including atrial fibrillation or heart failure. Detailed inclusion and exclusion criteria are listed in box 1.

Trial intervention

Patients in the intervention group will receive treatment with alirocumab 75 mg subcutaneously every 2 weeks for a total of 26 weeks. High-intensity statins, including rosuvastatin 20 mg or atorvastatin 40–80 mg, will be administered to both groups (figure 1). Patients not receiving high-intensity statins must have documented evidence. In such situations, moderate-intensity statins and/or

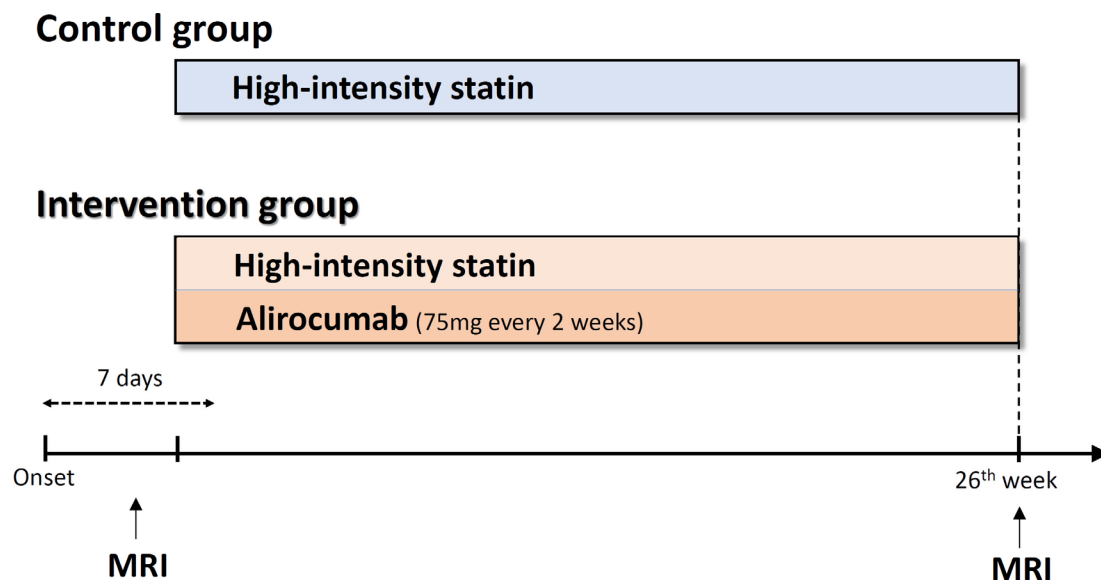


Figure 1 Schematic of the study design and treatment schedule. High-intensity statins, including rosuvastatin 20 mg or atorvastatin 40–80 mg, will be administered in both groups for 26 weeks. Patients in the intervention group will receive an additional treatment of alirocumab 75 mg subcutaneously within 7 days of stroke onset and then every 2 weeks for a total of 26 weeks. All patients will undergo MRI at recruitment and after 26 weeks.

ezetimibe is acceptable and this will be judged by the clinical physician.

Patients will receive high-intensity statins treatment for 26 weeks but a reduced dose is allowed if any adverse effects, including elevated creatine-phospho-kinase (CPK), myalgia, elevated liver functions or other side effects as judged by the clinical physician. We will check alanine aminotransferase (ALT) and CPK 4 weeks after treatment and follow-up measuring ALT, CPK and lipid profiles 12 and 26 weeks after treatment.

We will record clinical data on sex, age, smoking status and a medical history of hypertension, diabetes mellitus, hypercholesterolaemia, prior stroke, congestive heart failure, atrial fibrillation and coronary artery disease. Systolic and diastolic blood pressure values, complete blood count and blood biochemistry will be determined on admission. Essential surveys for stroke etiologies including ECG and carotid Doppler will be performed. For patients with acute stroke of suspected embolic origin, they will receive echocardiography and 24 hours Holter monitoring.

Neurological deficits will be evaluated using the NIHSS at the date of recruitment and the 7th, 30th and 90th day after stroke onset. Clinical outcomes at the third and sixth months will be assessed by the modified Rankin Scale (mRS).

Study outcomes

Primary endpoints

Changes in intracranial atherosclerotic plaque in a vessel-wall MRI before and after 6-month treatment, calculated as per cent atheroma volume (PAV), stenosis degree and enhancement volume.

The stenosis degree is calculated as: $(1 - \text{lumen area of stenotic lesion} / \text{reference lumen area}) \times 100\%$.

$$\text{PAV} = \frac{\Sigma(\text{EEM area} - \text{Lumen area})}{\Sigma \text{EEM area}} \times 100$$
 where the EEM area is the cross-sectional area of the external elastic membrane and Lumen area is the cross-sectional area of the lumen.

Enhancement volume is measured as postcontrast plaque enhancement for intracranial arteries and intraplaque haemorrhage.

Secondary endpoints

1. Percentage of patients with major cardiovascular events, including a composite of cardiovascular death, myocardial infarction, TIA, ischaemic stroke and haemorrhagic stroke.
2. Percentage of patients with myocardial infarction.
3. Percentage of patients with cardiovascular death.
4. Percentage of patients who had a stroke, including TIA, ischaemic and haemorrhagic stroke.
5. Percentage of patients who had an ischaemic stroke or TIA.
6. Percentage of patients with new ischaemic lesions, defined as new ischaemic lesions in the territory of ICAS between two MRIs.
7. Percentage of patients with favourable functional recovery, defined as mRS at 3 and 6 months.
8. The changes of liver function tests, HbA1c and lipid profiles.

Sample size

There was no reference for the changes of intracranial plaques after PCSK9 treatment. Therefore, sample size is determined by biostatistical calculation using G*POWER based on expected effect size of 0.7, which is the mean difference in SD units detectable with 80% power at a 2-sided 0.05 level of significance with 2-sample t-test and the SD fraction, which is SD as a fraction of biologically

**Box 1 Inclusion and exclusion criteria****Inclusion criteria**

- ▶ Clinical diagnosis of acute ischaemic stroke.
- ▶ A total score of 1–15 in National Institutes of Health Stroke Scale.
- ▶ Ischaemic lesions on diffuse-weighted imaging located in the territory of symptomatic intracranial atherosclerosis (ICAS).
- ▶ Symptomatic ICAS (above 30%) at the intracranial portion of the internal carotid artery, at the M1 or M2 of the middle cerebral artery, or at the basilar artery.
- ▶ Serum low-density lipoprotein cholesterol (LDL-C) ≥ 70 mg/dL for subjects on lipid-lowering therapies (such as a statin and/or ezetimibe) or LDL-C ≥ 100 mg/dL for subjects without lipid-lowering therapies.
- ▶ Ability to randomise within 7 days of time last known to be free of new ischaemic symptoms.
- ▶ Ability to receive alirocumab or statin treatment within 7 days of stroke onset.
- ▶ Head CT or MRI ruling out haemorrhage or other pathology, such as vascular malformation, tumour or abscess, that could explain symptoms or contraindicate therapy.
- ▶ Prestroke modified Rankin Scale ≤ 2 .

Exclusion criteria

- ▶ Age < 20 years.
- ▶ After endovascular intervention or endarterectomy for symptomatic ICAS.
- ▶ The magnetic resonance angiography shows $> 50\%$ stenosis of extracranial carotid or vertebral arteries.
- ▶ Patients have high-risk sources of cardiac embolism, including acute myocardial infarction, atrial fibrillation, valvular heart disease or severe heart failure.
- ▶ Other determined stroke subtype, including arterial dissection, shock, vasculitis, antiphospholipid antibody syndrome, cerebral autosomal dominant arteriopathy with subcortical infarcts and leukoencephalopathy etc.
- ▶ Qualifying ischaemic stroke induced by angiography or surgery.
- ▶ Severe non-cardiovascular comorbidity with a life expectancy < 6 months.
- ▶ Contraindication or allergy to alirocumab or gadolinium.
- ▶ Renal insufficiency with serum creatinine > 2 mg/dL or calculated glomerular filtration rate < 30 mL/min/1.73 m² by estimated glomerular filtration rate using Cockcroft Gault methodology.
- ▶ Abnormal hepatic functions (alanine aminotransferase > 40 U/L, international normalized ratio (INR) > 1.2 , variceal bleeding, jaundice or hepatic encephalopathy).
- ▶ Systemic bleeding or haemostatic disorder in recent 3 months.
- ▶ Thrombocytopenia with platelet count $< 100 \times 10^9$ /L or leucopenia with decreased cell count $< 2 \times 10^9$ /L.
- ▶ Anaemia (< 10 mg/dL).
- ▶ History of drug-induced haematologic or hepatic abnormalities.
- ▶ History of malignancy that required surgery, radiation therapy or systemic therapy.
- ▶ Females who are pregnant or nursing, or who are of childbearing potential and unwilling to use effective contraception.
- ▶ Any neurological conditions that complicate outcome assessment during follow-up.

meaningful difference. The intervention group has a sample size of 20 and the control group has a sample size of 40. However, considering a possible dropout of 10%, sample size is estimated to be 22 and 44, respectively.

Imaging protocol and analysis

All data will be obtained using a Siemens Verio 3T MRI scanner (Siemens Medical System) with a 32-channel head coil. A standard protocol is used for the initial and follow-up imaging including: (1) T2-weighted turbo spin-echo (TSE) imaging, (2) fluid-attenuated inversion recovery (FLAIR) imaging, (3) DWI, (4) three-dimensional (3-D) time-of-flight MR angiography and (5) high-resolution vessel wall imaging.^{24 25}

The imaging sequences and parameters are as follows: T2-weighted TSE imaging (repetition time (TR)/echo time (TE)=2800/90 ms, 245×320 acquisition matrix, 4.0 mm slice thickness and 28 slices), FLAIR imaging (TR/TE=8000/93 ms, inversion time=2400 ms, 320×256 acquisition matrix, 4.0 mm slice thickness, 28 slices and 230×320 mm field of view (FOV)) and DWI (TR/TE=8400/90, 160×160 acquisition matrix, 4.0 mm slice thickness, 28 slices, b-factor=1300 and 230×230 mm field of view (FOV)). The MR angiography used 3-D time of flight (TR/TE=20/3.6 ms and 0.8 mm thickness) covering the extracranial carotid artery and the circle of Willis.²⁶

The high-resolution vessel wall imaging includes precontrast and postcontrast 3D T1-weighted Sampling Perfection with Application optimised Contrast using different flip angle Evolution sequence imaging (0.6×0.6×0.6 mm voxel size, TR/TE=700/22 ms, acquisition matrix=320×320 pixels, FOV=190×190 mm and 44 slices with zero gap) in multiple planes and fat-saturated, moderately T2-weighted 3-D TSE imaging (0.6×0.6×0.6 mm voxel size, TR/TE=3200/323 ms, acquisition matrix=320×320 pixels, FOV=180×150 mm and 44 slices with zero gap).

Time-of-flight MRA is used to select the location of maximal stenosis by the cross-section of luminal images, which include axial images for basilar artery and sagittal images for MCA. The plaque resulting in highest degree of stenosis is selected for analysis. The outer vessel contours are traced on T2-weighted images and lumen contours are traced on T1-weighted images.¹⁴ After tracing the lumen area and vessel area, the wall area is defined as the difference between the vessel and lumen areas (wall area=vessel area–lumen area). We select a normal vessel as a reference, either a normal vessel contralaterally or a proximal portion before the stenosis.

One experienced neuroradiologist and one neurologist will assess the MRI, both blinded to the clinical information.

Statistical analysis

The statistical analyses will be performed using the IBM Statistical Package for the Social Sciences V.18 software. The Kolmogorov-Smirnov test will be used to examine the normality of continuous variables. Categorical data will be analysed using Fisher's exact test or Pearson's χ^2 test, as appropriate. Normally distributed continuous variables will be compared by an independent samples Student's t-test and the variables not normally distributed will be compared by a Mann-Whitney U test. A logistic regression

model will be applied to adjust confounding factors for the measured outcomes. HRs and 95% CIs will be estimated with the use of a Cox proportional-hazards model for the secondary end points. A p value of <0.05 will be considered statistically significant.

Data management

All informed consent forms and completed documents will be kept in a secure locked facility. All the clinical data will be input into an electronic database and only the principal researchers have the rights to access. A research steering committee will be established to monitor the progress and safety of this study in accordance with the required quality standards. The research assistants will verify compliance with all consent forms, research protocols and procedures, and data review. The researchers will report to the research steering committee every 6 months. All documents and records will be stored for 7 years after this trial is completed.²⁷

Adverse events

Any adverse events that occur during the conduct of the trial will be reported to the Domain Specific Research Board in accordance with local agency policies. Interim analyses are used to help decide whether to stop or continue the trial according to the accumulated data.

Patient and public involvement

Stroke association members took part in the preparation of the proposal. Selected patients with acute symptomatic ICAS will participate in this study. Stroke associations will help to disseminate research findings to the public.

ETHICS AND DISSEMINATION

The study has been approved by the Institutional Review Committee of Chang Gung Memorial Hospital (approval no. 202 002 482A3). The study is registered on ClinicalTrials.gov (NCT05001984). All participants will be required to sign and date an informed consent (online supplemental file). The results of this research will be disseminated in peer-reviewed journals and academic conferences. The dataset obtained during the research period can be obtained from the corresponding author on reasonable request.

Author affiliations

¹Department of Neurology, Chang Gung Memorial Hospital Chiayi Branch, Chiayi County, Taiwan

²College of Medicine, Chang Gung University, Taoyuan, Taiwan

³College of Nursing and Graduate Institute of Nursing, Chang Gung University of Science and Technology, Chiayi, Taiwan

⁴Department of Diagnostic Radiology, Chang Gung Memorial Hospital Chiayi Branch, Chiayi County, Taiwan

⁵College of Nursing, Chang Gung University of Science and Technology, Chiayi County, Taiwan

⁶Department of Emergency Medicine, Chang Gung Memorial Hospital Chiayi Branch, Chiayi County, Taiwan

Twitter Hsu-Huei Weng @lukeweng

Contributors Y-CH designed the initial protocol, drafted the manuscript and received the funding. J-DL, C-HC, L-CL, H-HW and Y-HT amended the initial protocol. All authors read and approved of the protocol prior to submission.

Funding This work is supported by a Ministry of Science and Technology research grant (MOST 110-2314-B-182A-072).

Competing interests None declared.

Patient and public involvement Patients and/or the public were involved in the design, or conduct, or reporting, or dissemination plans of this research. Refer to the Methods section for further details.

Patient consent for publication Not applicable.

Provenance and peer review Not commissioned; externally peer reviewed.

Supplemental material This content has been supplied by the author(s). It has not been vetted by BMJ Publishing Group Limited (BMJ) and may not have been peer-reviewed. Any opinions or recommendations discussed are solely those of the author(s) and are not endorsed by BMJ. BMJ disclaims all liability and responsibility arising from any reliance placed on the content. Where the content includes any translated material, BMJ does not warrant the accuracy and reliability of the translations (including but not limited to local regulations, clinical guidelines, terminology, drug names and drug dosages), and is not responsible for any error and/or omissions arising from translation and adaptation or otherwise.

Open access This is an open access article distributed in accordance with the Creative Commons Attribution Non Commercial (CC BY-NC 4.0) license, which permits others to distribute, remix, adapt, build upon this work non-commercially, and license their derivative works on different terms, provided the original work is properly cited, appropriate credit is given, any changes made indicated, and the use is non-commercial. See: <http://creativecommons.org/licenses/by-nc/4.0/>.

ORCID iDs

Yen-Chu Huang <http://orcid.org/0000-0001-7885-6376>

Yuan-Hsiung Tsai <http://orcid.org/0000-0003-4906-0365>

Hsu-Huei Weng <http://orcid.org/0000-0002-2020-8912>

REFERENCES

- Holmstedt CA, Turan TN, Chimowitz MI. Atherosclerotic intracranial arterial stenosis: risk factors, diagnosis, and treatment. *Lancet Neurol* 2013;12:1106–14.
- Wang Y, Zhao X, Liu L, *et al*. Prevalence and outcomes of symptomatic intracranial large artery stenoses and occlusions in China: the Chinese intracranial atherosclerosis (CICAS) study. *Stroke* 2014;45:663–9.
- Hurford R, Wolters FJ, Li L, *et al*. Prevalence, predictors, and prognosis of symptomatic intracranial stenosis in patients with transient ischaemic attack or minor stroke: a population-based cohort study. *Lancet Neurol* 2020;19:413–21.
- Gao S, Wang YJ, Xu AD, *et al*. Chinese ischemic stroke subclassification. *Front Neurol* 2011;2:6.
- Xu W. High-resolution MRI of intracranial large artery diseases: how to use it in clinical practice? *Stroke Vasc Neurol* 2019;4:102–4.
- Xu W-H, Li M-L, Gao S, *et al*. Middle cerebral artery intraplaque hemorrhage: prevalence and clinical relevance. *Ann Neurol* 2012;71:195–8.
- Petrone L, Nannoni S, Del Bene A, *et al*. Branch atheromatous disease: a clinically meaningful, yet unproven concept. *Cerebrovasc Dis* 2016;41:87–95.
- Yamamoto Y, Ohara T, Hamanaka M, *et al*. Characteristics of intracranial branch atheromatous disease and its association with progressive motor deficits. *J Neurol Sci* 2011;304:78–82.
- Kim JS, Yoon Y. Single subcortical infarction associated with parental arterial disease: important yet neglected sub-type of atherothrombotic stroke. *Int J Stroke* 2013;8:197–203.
- Liu D, Liu J, Cai Y, *et al*. Is the future of symptomatic intracranial atherosclerotic stenosis management promising? *J Neurol Neurosurg Psychiatry* 2020;91:122–4.
- Johnston SC, Easton JD, Farrant M, *et al*. Clopidogrel and aspirin in acute ischemic stroke and high-risk TIA. *N Engl J Med* 2018;379:215–25.
- Wang Y, Wang Y, Zhao X, *et al*. Clopidogrel with aspirin in acute minor stroke or transient ischemic attack. *N Engl J Med* 2013;369:11–19.
- Kim D, Park J-M, Kang K, *et al*. Dual versus mono antiplatelet therapy in large atherosclerotic stroke. *Stroke* 2019;50:1184–92.



- 14 Chimowitz MI, Lynn MJ, Derdeyn CP, *et al.* Stenting versus aggressive medical therapy for intracranial arterial stenosis. *N Engl J Med* 2011;365:993–1003.
- 15 Chimowitz MI, Lynn MJ, Howlett-Smith H, *et al.* Comparison of warfarin and aspirin for symptomatic intracranial arterial stenosis. *N Engl J Med* 2005;352:1305–16.
- 16 Amarenco P, Bogousslavsky J, Callahan A, *et al.* High-dose atorvastatin after stroke or transient ischemic attack. *N Engl J Med* 2006;355:1374–59.
- 17 Grundy SM, Stone NJ, Bailey AL. AHA/ACC/AACVPR/AAPA/ABC/ACPM/ADA/AGS/APhA/ASPC/NLA/PCNA guideline on the management of blood cholesterol: a report of the American College of Cardiology/American Heart Association Task Force on clinical practice guidelines. *Circulation* 2018;2019:e1082–143.
- 18 Stone NJ, Robinson JG, Lichtenstein AH. ACC/AHA guideline on the treatment of blood cholesterol to reduce atherosclerotic cardiovascular risk in adults: a report of the American College of Cardiology/American Heart Association Task Force on Practice Guidelines. *Circulation* 2013;2014:S1–45.
- 19 Averna M, Banach M, Bruckert E, *et al.* Practical guidance for combination lipid-modifying therapy in high- and very-high-risk patients: a statement from a European Atherosclerosis Society Task Force. *Atherosclerosis* 2021;325:99–109.
- 20 Schwartz GG, Steg PG, Szarek M, *et al.* Alirocumab and cardiovascular outcomes after acute coronary syndrome. *N Engl J Med* 2018;379:2097–107.
- 21 Sabatine MS, Giugliano RP, Keech AC, *et al.* Evolocumab and clinical outcomes in patients with cardiovascular disease. *N Engl J Med* 2017;376:1713–22.
- 22 Guedeney P, Giustino G, Sorrentino S, *et al.* Efficacy and safety of alirocumab and evolocumab: a systematic review and meta-analysis of randomized controlled trials. *Eur Heart J* 2019;0:1–9.
- 23 Chung J-W, Cha J, Lee MJ, *et al.* Intensive statin treatment in acute ischaemic stroke patients with intracranial atherosclerosis: a high-resolution magnetic resonance imaging study (STAMINA-MRI study). *J Neurol Neurosurg Psychiatry* 2020;91:204–11.
- 24 Mandell DM, Mossa-Basha M, Qiao Y, *et al.* Intracranial vessel wall MRI: principles and expert consensus recommendations of the American Society of Neuroradiology. *AJNR Am J Neuroradiol* 2017;38:218–29.
- 25 Mossa-Basha M, Hwang WD, De Havenon A, *et al.* Multicontrast high-resolution vessel wall magnetic resonance imaging and its value in differentiating intracranial vasculopathic processes. *Stroke* 2015;46:1567–73.
- 26 Huang Y-C, Lee J-D, Pan Y-T, *et al.* Perfusion defects and collateral flow patterns in acute small subcortical infarction: a 4D dynamic MRI study. *Transl Stroke Res* 2021:00953-x. doi:10.1007/s12975-021-00953-x
- 27 Huang Y-C, Lee J-D, Weng H-H, *et al.* Statin and dual antiplatelet therapy for the prevention of early neurological deterioration and recurrent stroke in branch atheromatous disease: a protocol for a prospective single-arm study using a historical control for comparison. *BMJ Open* 2021;11:e054381.