

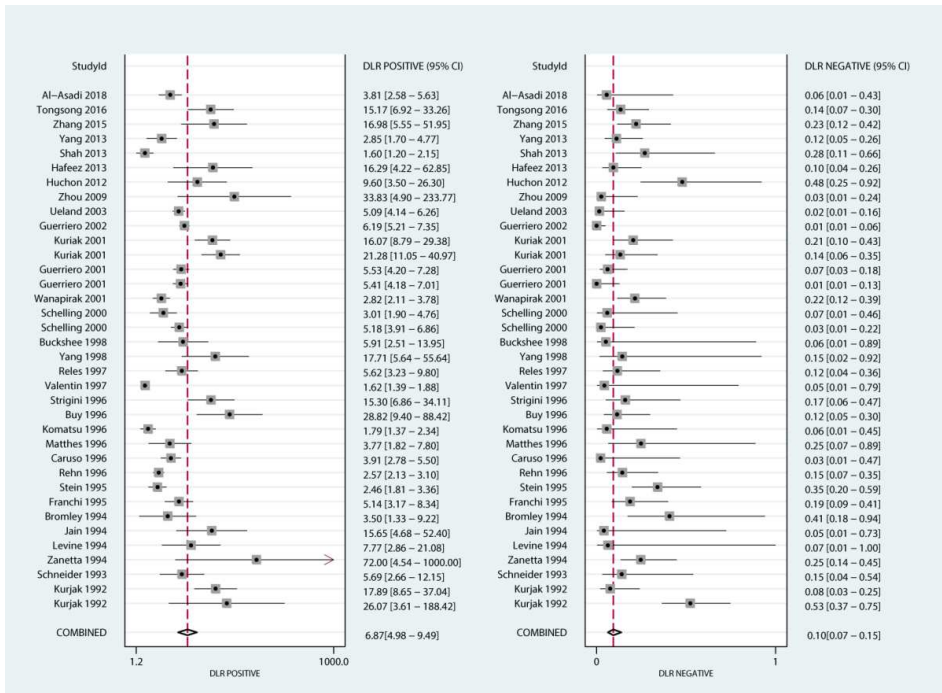Figure S1. The pooled PLR and NLR for US differentiate the benign and malignant ovarian masses

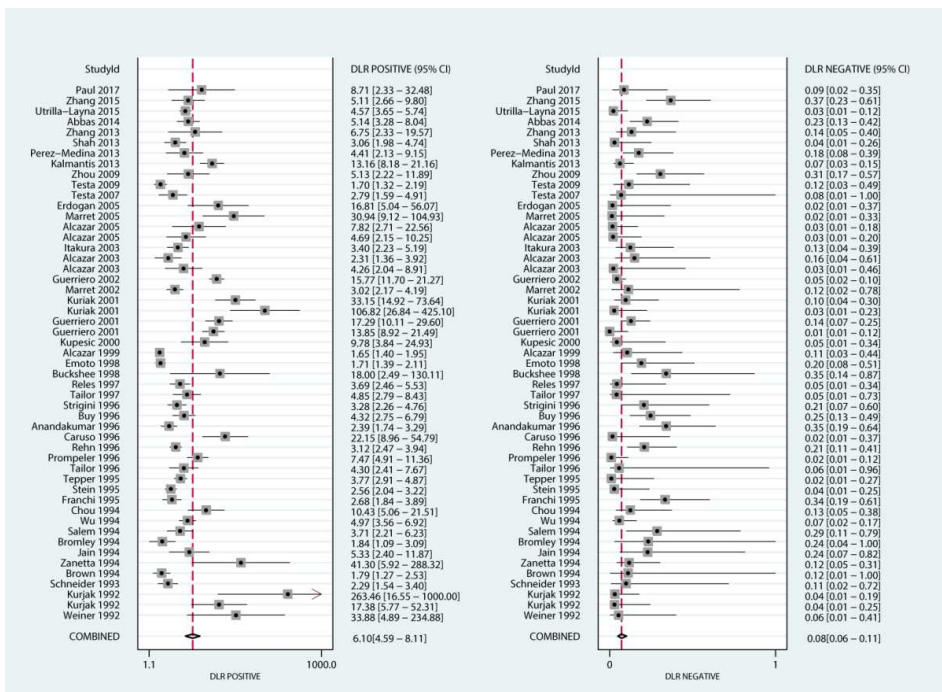


Figure S2. The pooled PLR and NLR for Doppler US differentiate the benign and malignant ovarian masses

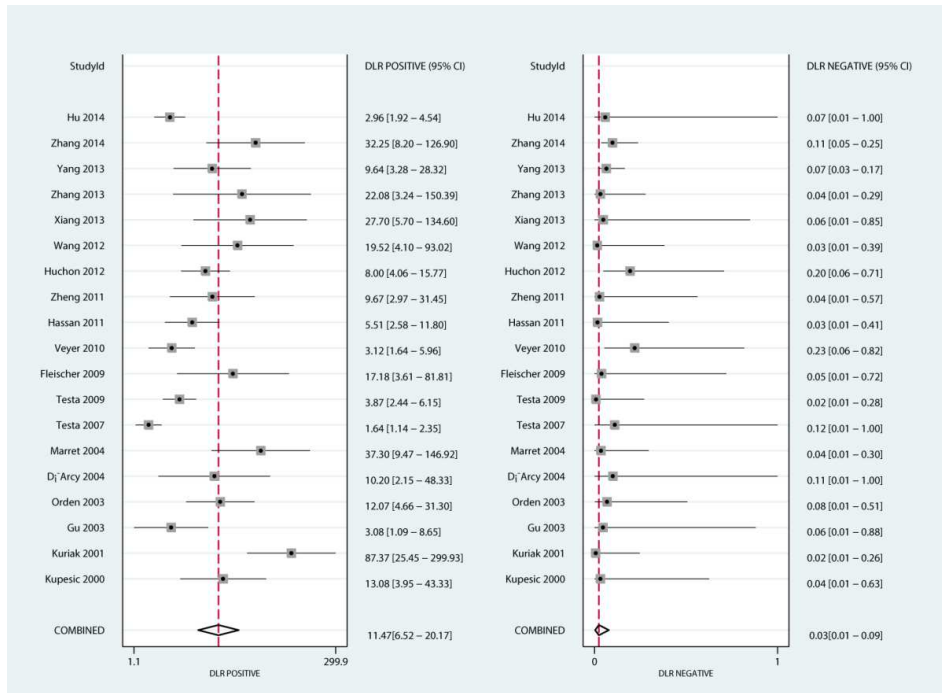


Figure S3. The pooled PLR and NLR for CEUS differentiate the benign and malignant ovarian masses